

The Mystery of Morgellons Disease

Infection or Delusion?

Virginia R. Savely,¹ Mary M. Leita² and Raphael B. Stricker³

1 South Austin Family Practice Clinic, Austin, Texas, USA

2 Morgellons Research Foundation, McMurray, Pennsylvania, USA

3 California Pacific Medical Center, San Francisco, California, USA

Abstract

Morgellons disease is a mysterious skin disorder that was first described more than 300 years ago. The disease is characterized by fiber-like strands extruding from the skin in conjunction with various dermatologic and neuropsychiatric symptoms. In this respect, Morgellons disease resembles and may be confused with delusional parasitosis. The association with Lyme disease and the apparent response to antibacterial therapy suggest that Morgellons disease may be linked to an undefined infectious process. Further clinical and molecular research is needed to unlock the mystery of Morgellons disease.

1. Background

Delusional parasitosis, or Ekbom syndrome, is a psychiatric disorder in which patients mistakenly believe that they are infested with a skin parasite.^[1-4] Patients often refuse to accept a psychiatric diagnosis for their skin symptoms and findings, and they continue to insist that they have a parasitic infestation. In medical school, physicians learn of the ‘matchbox sign’ of delusional parasitosis, so-called because patients carry samples of ‘hair’, ‘lint’, or ‘fuzz’ to the physician in a matchbox in a desperate attempt to provide evidence of the agent responsible for their torment. When two people describe symptoms of delusional parasitosis, the condition is termed *folie à deux* (madness of two).^[5] There is also *folie à trois* (madness of three) and *folie à quatre* (madness of four). Delusional parasitosis affecting all members of a family is considered *folie à famille* (madness of family).^[6] Antipsychotic medications such as pimozide or risperidone are often prescribed for these patients.^[3,7]

The first author of this report (Virginia Savely) began seeing patients with symptoms of delusional parasitosis in her clinical practice in 2002, when several patients with chronic, debilitating illnesses alerted her to their non-healing skin lesions. These patients also experienced crawling and stinging sensations under the skin, as well as the presence of fiber-like strands and granule-like objects associated with skin lesions. With the aid of a 60× hand-

held digital microscope, a network of blue fibers under the skin of these patients was visualized, as well as blue and white fibers protruding from their lesions. Attempts to remove the tough filaments protruding from the skin lesions led patients to experience shooting pains radiating from the site, indicating that the filaments were not simply adsorbed to the skin and might be quite resistant to extraction.

A colleague informed Ms Savely that the Morgellons Research Foundation had described a disease matching the symptoms that she had observed in her patients. She contacted the foundation and was informed that her state, Texas, was second only to California in the number of reports of this bizarre disease, which was being called Morgellons disease.

2. History

The name ‘Morgellons disease’ is based on a disease described in 1674 by Sir Thomas Browne, as follows: “Hairs which have most amused me have not been in the face or head, but on the Back, and not in Men but Children, as I long ago observed in that endemial distemper of little Children in Languedock, called the Morgellons, wherein they critically break out with harsh Hairs on their Backs, which takes off the unquiet symptoms of the Disease, and delivers them from Coughs and Convulsions.”^[8]

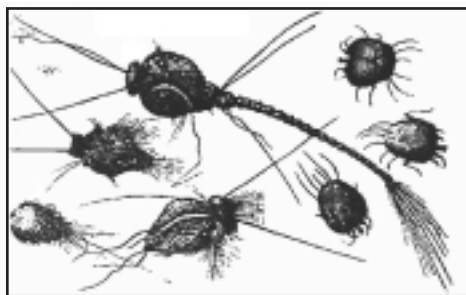


Fig. 1. Ettmuller's drawings of Morgellons fibers, 1682^[8] (courtesy of Morgellons Research Foundation, copyright © 2005).

Dr Michel Ettmuller's microscopic drawings, dating from 1682, of objects associated with what was then believed to be a worm infestation of children (figure 1) appear to be similar to microscopic views of fibers from present-day sufferers of this disease.^[8]

The Morgellons Research Foundation began accepting registrations from people with symptoms of this unrecognized disease in 2002. The original focus of the foundation was on skin symptoms, but it soon became evident that other symptoms within this patient group, such as disabling fatigue, life-altering cognitive decline, joint pain, and mood disorders were of much greater concern.

3. Symptoms

Patients with Morgellons disease typically have symptoms that include insect-like sensations (i.e. crawling, stinging, and biting sensations) as well as skin lesions, which can be anything from minor to disfiguring in their appearance (figure 2). Fiber-like material can often be removed from skin lesions as either single strands (figure 3) or what appear to be balls of wound fibrous material, and the fibers may demonstrate autofluorescence (figure 4). Patients frequently describe this material as 'fibers', 'fiber balls', or 'fuzz balls'. Granules removed from the skin of patients can often be seen microscopically to have one or more fibers attached at the ends. Patients often describe these granules as 'seeds', 'eggs', or 'sand'. Many individuals report material described as 'black specks' or 'black oil'. Some patients have no observable skin lesions and have intact skin, with the skin sensations and fibrous, granular, or black material being the only apparent indicators of the disease.

According to statistics from the Morgellons Research Foundation, the majority (95%) of affected patients report symptoms of disabling fatigue and self-described 'brain fog' or problems with attention. Patients also report a high incidence (50%) of fibromyalgia, joint pain, and sleep disorders. Other symptoms include hair loss, decline in vision, neurologic disorders, and occasionally

disintegration of teeth in the absence of caries or gingivitis. Most patients are unable to continue working, and those who are able to continue working report that they do not function optimally.

The vast majority of patients with this disease have been diagnosed with a psychosomatic illness. Typically, patients have sought help from between 10 and 40 physicians and report that their symptoms are not taken seriously. Patients report that physicians do not even conduct a thorough examination but make an instant diagnosis of delusional parasitosis and attribute the obvious open sores on the patient's skin to attempts at self-mutilation. One

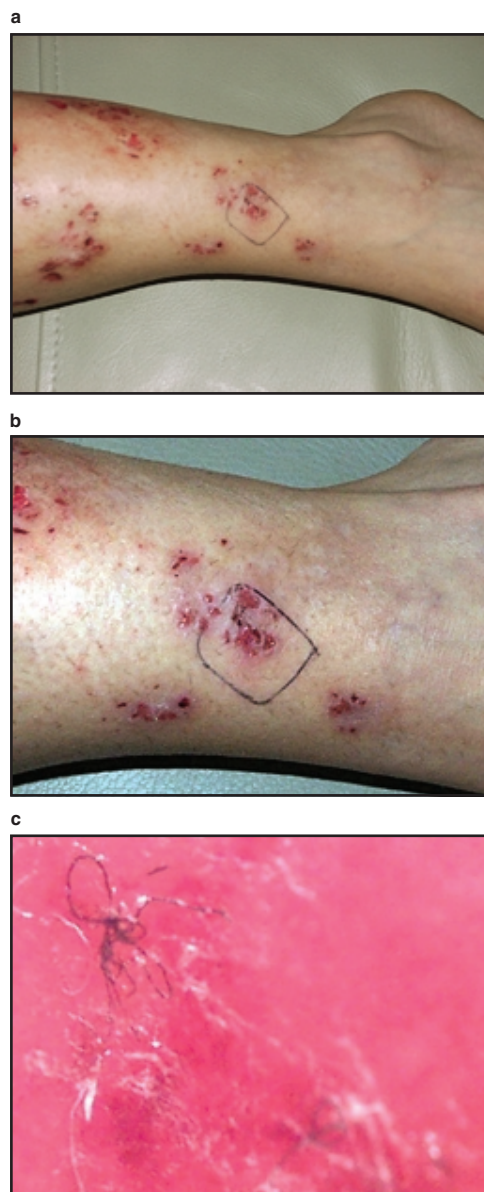

Fig. 2. Clinical appearance of Morgellons skin lesions: (a) and (b) gross appearance of leg lesions; (c) appearance of subcutaneous fibers under 60× digital microscope (courtesy of Charles Holman, copyright © 2005).




Fig. 3. Scanning electron micrograph of fibers emerging from skin lesion under 250× microscope (courtesy of Morgellons Research Foundation, copyright © 2005).

patient described his experience of the disease in this way: “I have had this disease for 20 years. I spent the first 10 years going from doctor to doctor for help. I spent the last 10 years just living with it, knowing that no one would ever help me.”

The high incidence of psychopathology, which appears to be directly attributable to this disease, confounds the clinical picture for these patients as they seek validation for an insidious dermatologic condition that defies logic, while sometimes exhibiting obvious symptoms of mental illness. It appears that the putative underlying infectious disease, which has been unrecognized and untreated, can cause psychopathology in many patients. This observation underscores a basic premise of psychosomatic dermatology: the diagnosis of a delusional disorder must be based on the presence of a primary psychiatric disorder rather than the absence of known dermatopathology. In the case of Morgellons disease, a poorly characterized dermatologic condition appears to trigger secondary psychopathology that may be wrongly confused with a primary delusional disorder.

4. Epidemiology and Transmission

The US states of California, Texas, and Florida appear to have the highest number of reports of Morgellons disease, with primary clusters noted in Los Angeles and San Francisco, California, and in Houston, Dallas, and Austin, Texas. California accounts for 26% of cases in the US. All 50 US states and 15 nations, including Canada, the UK, Australia, and the Netherlands, have reported cases of Morgellons disease. The total number of registrations on the Morgellons Research Foundation website is presently 2200, which is believed to be a fraction of the actual number of cases.

The two main occupational groups reporting symptoms of Morgellons disease are nurses and teachers. Nurses outnumber

teachers 3 : 1, but both occupational groups represent a significant percentage of patients with this disease. It is unclear what the risk factors for these two occupational groups might be, but the possibility of casual transmission of infectious agents has been entertained.

There is some evidence to suggest that skin lesions and fibers may not be readily apparent in all individuals with this disease, as family members of patients often report similar systemic disease symptoms without skin symptoms. Whether the disease is transmissible by human contact remains unclear. Although most people with Morgellons disease are fearful of infecting family members, families in which all members are affected often have suspected simultaneous exposure to an inciting agent. Contact with soil or waste products also appears to be associated with the disease.

Patients have reported symptoms of this disease in their pets. The majority of reports involve dogs, but cats appear to be increasingly affected. There have also been recent reports of horses with skin lesions fitting the description of Morgellons lesions. Several horse owners have observed fibers associated with skin lesions on their animals by using lighted 30× hand-held microscopes.

5. Pathophysiology

Skin biopsies of patients with Morgellons disease typically reveal nonspecific pathology or an inflammatory process with no observable pathogens. Several biopsies have shown fibrous material projecting from inflamed epidermal tissue. There is some speculation that the fibrous (and other) material associated with

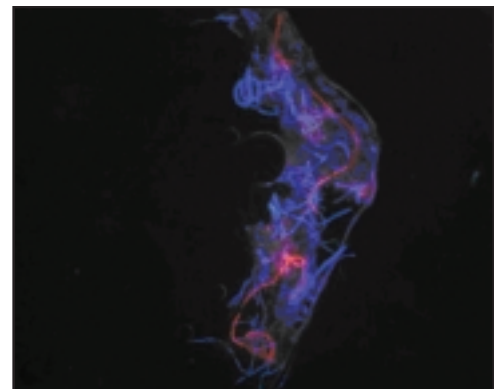


Fig. 4. Image showing striking autofluorescence of fibers from Morgellons skin lesion. Nothing was added to the skin sample except Gel/Mount mounting media and the coverslip. The image is an overlay of red and blue images. Imaging was done using an Olympus Provis Microscope that employs standard wavelengths for rhodamine (excitation 550nm per emission 565nm) and fluoroscein/alexa 488 (excitation 494nm per emission 519nm) [courtesy of Morgellons Research Foundation, copyright © 2005].

skin lesions may be linked to the biofilm of a bacteria, *Stenotrophomonas maltophilia*, and this possibility requires further histopathologic investigation. In general, pathologists look for signs of known diseases and, thus, may miss clues of Morgellons disease in biopsies.

There is preliminary information that Morgellons fibers are made of cellulose, but this information has been neither formally evaluated nor confirmed. In a classic study, Hall et al.^[9] identified fibers composed of a cellulose-protein complex as a minor constituent of mammalian connective tissue, and increased amounts of these fibers were noted in tissue from patients with scleroderma and other pathologic skin conditions. More recent research has demonstrated synthesis of cellulose fibers by certain Gram-negative bacteria and fungi.^[10-13] Studies using newer carbohydrate microarray technologies may unlock the mystery of these fibers.^[14]

6. Differential Diagnosis and Association with Lyme Disease

Differential diagnoses of Morgellons disease includes filariasis and the perforating dermatoses. Filariasis is a tropical nematode infestation characterized by pruritic skin lesions and lymphatic obstruction.^[15,16] Eosinophilia is common, and microfilariae are often identified in biopsy samples from skin lesions. In contrast, lymphatic obstruction and eosinophilia are rarely seen in Morgellons patients, and nematodes have not been identified in skin biopsy samples from these individuals. While filariasis may respond to treatment with antiparasitic medications such as ivermectin,^[16] antiparasitic therapy does not appear to be useful in treating Morgellons disease.

The perforating dermatoses are a group of skin diseases characterized by elimination of elastic or collagen fibers from the upper dermis through the skin.^[17-20] There are five members of this group: Kyrle's disease, perforating folliculitis, reactive perforating collagenosis, elastosis perforans serpiginosa, and acquired perforating dermatosis.^[17] The perforating dermatoses are associated with hereditary diseases including Ehlers-Danlos syndrome, osteogenesis imperfecta, Down syndrome, and Wilson disease. They may also be seen in patients with brittle diabetes mellitus or dialysis-dependent renal failure.^[17-20] These dermatoses are distinct from Morgellons disease because the protruding fibers are made up of elastic or collagenous tissue that is easily identified by histopathology.^[18] In addition, Morgellons patients generally do not have the rare hereditary conditions or severe metabolic abnormalities associated with the perforating dermatoses. Conversely,

systemic infection and neuropsychiatric symptoms have not been associated with these dermatoses, and they do not respond to antibacterial therapy.^[17-20]

Many patients with Morgellons disease have positive Western blots for *Borrelia burgdorferi*, the causative agent of Lyme disease. It appears that there may be a connection between the two diseases, with one infection possibly predisposing the individual to a second infectious agent. Whether all patients with Morgellons disease also have Lyme borreliosis remains to be seen.

The first author now has more than 80 patients in her practice who fit the criteria for Morgellons disease. These patients have come from all over the US, and the consistency of their stories is impressive. All but one of these patients have tested positive for Lyme borreliosis. When these patients are treated with antibacterials for their Lyme disease, remission of Morgellons symptoms is seen in most. This observation distinguishes Morgellons disease from the dermatologic conditions described above.

7. Discussion

Throughout history, the medical world has been reluctant to adopt new paradigms or concepts of disease. The philosopher Thomas Kuhn proposed that scientific communities operate within a rigid set of assumptions and, therefore, are not open to a paradigm shift when confronted by an anomaly.^[21] As examples, the Hungarian physician Ignaz Semmelweis was ridiculed in the 1850s in Vienna for suggesting that childbed fever was caused by an infectious agent, while syphilis patients were confined to mental institutions before it was realized that they had an infectious disease.

It is possible that the medical community is overlooking an important and previously unrecognized skin infection, dooming patients to endless frustration and suffering by not validating or attempting to treat this chronic infection.^[22] The few medical professionals who have become involved with the diagnosis and treatment of Morgellons disease are becoming increasingly convinced that many patients have a puzzling infectious disease that may cause horrific symptoms and psychiatric sequelae.

Until a formal study of Morgellons disease is initiated, the cause, transmission, and treatment of the disease remain uncertain. The Texas Department of Health (TDH) was first alerted by the Morgellons Research Foundation to the occurrence of this disease in Texas in 2002. Subsequently, the TDH conferred with the Centers for Disease Control and Prevention (CDC), but to date neither the TDH nor the CDC has initiated an investigation into the disease. As the number of documented cases rises, it is the hope of

the authors that governmental health authorities will take note and begin to support investigation into the cause and epidemiology of the disease.

8. Conclusions

More than 300 years after its initial description, Morgellons disease remains a medical mystery. The disease has defied investigation and continues to present a diagnostic puzzle to healthcare providers. In this situation, medical practitioners must look beyond what they have been taught when confronted with new and puzzling symptoms in patients. Rather than being quick to pigeon-hole Morgellons patients into a psychiatric diagnosis such as delusional parasitosis, practitioners should take patient complaints seriously and attempt to investigate the chronic symptoms of the disease.

Sir William Osler, one of the greatest physicians, humanitarians, and teachers of the 19th century, taught that "Medicine is learned by the bedside and not in the classroom". Recognition of Morgellons disease will serve as a reminder to medical practitioners that we have much to learn from listening to the patient. At the same time, newer molecular techniques will hopefully unlock the secrets of this devastating illness.

Acknowledgements

This work was supported in part by the Morgellons Research Foundation (McMurray, PA, USA) and the International Lyme and Associated Diseases Society (ILADS; Bethesda, MD, USA). The authors thank Drs J. Kurt Frederick, Alan MacDonald, Steven Phillips, Joseph Burrascano, Kenneth Liegner, Richard Horowitz, and Ann Corson for helpful discussion; Charles Holman for providing figures used in the article; and Diane Gay for patient care. The authors declare that they have no conflicts of interest related to the contents of this article.

References

- Ait-Ameur A, Bern P, Firoloni MP, et al. Delusional parasitosis or Ekbom's syndrome. *Rev Med Interne* 2000; 21: 182-6
- Koo J, Gambla C. Delusions of parasitosis and other forms of monosymptomatic hypochondriacal psychosis: general discussion and case illustrations. *Dermatol Clin* 1996; 14: 429-38
- Koo J, Lee CS. Delusions of parasitosis: a dermatologist's guide to diagnosis and treatment. *Am J Clin Dermatol* 2001; 2: 285-90
- Wilson FC, Uslan DZ. Delusional parasitosis. *Mayo Clin Proc* 2004; 79: 1470
- Bourgeois ML, Duhamel P, Verdoux H. Delusional parasitosis: folie à deux and attempted murder of a family doctor. *Br J Psychiatry* 1992; 161: 709-11
- Daniel E, Srinivasan TN. Folie à famille: delusional parasitosis affecting all the members of a family. *Indian J Dermatol Venereol Leprol* 2004; 70: 296-7
- Lorenzo CR, Koo J. Pimozide in dermatologic practice: a comprehensive review. *Am J Clin Dermatol* 2004; 5: 339-49
- Kellett CE. Sir Thomas Browne and the disease called the Morgellons. *Ann Med Hist* 1935; 7: 467-9
- Hall DA, Happey F, Lloyd PF, et al. Oriented cellulose as a component of mammalian tissue. *Proc R Soc Lond B Biol Sci* 1960; 151: 497-516
- Matthysse AG, White S, Lightfoot R. Genes required for cellulose synthesis in *Agrobacterium tumefaciens*. *J Bacteriol* 1995; 177: 1069-75
- Bertocchi C, Delneri D, Signore S, et al. Characterization of microbial cellulose from a high-producing mutagenized *Acetobacter pasteurianus* strain. *Biochim Biophys Acta* 1997; 1336: 211-7
- Brown RM. Cellulose structure and biosynthesis. *Pure Appl Chem* 1999; 71: 204-12
- Polizeli ML, Rizzatti AC, Monti R, et al. Xylanases from fungi: properties and industrial applications. *Appl Microbiol Biotechnol* 2005; 67: 577-91
- Wang D. Carbohydrate microarrays. *Proteomics* 2003; 3: 2167-75
- Melrose WD. Lymphatic filariasis: new insights into an old disease. *Int J Parasitol* 2002; 32: 947-60
- Melrose WD. Chemotherapy for lymphatic filariasis: progress but not perfection. *Expert Rev Anti Infect Ther* 2003; 1: 571-7
- Sehgal VN, Jain S, Thappa DM, et al. Perforating dermatoses: a review and report of four cases. *J Dermatol* 1993; 20: 329-40
- Rapini RP, Herbert AA, Drucker CR. Acquired perforating dermatosis: evidence for combined transepidermal elimination of both collagen and elastic fibers. *Arch Dermatol* 1989; 125: 1074-8
- Mehta RK, Burrows NP, Payne CM, et al. Elastosis perforans serpiginosa and associated disorders. *Clin Exp Dermatol* 2001; 26: 521-4
- Becuwe C, Dalle S, Ronger-Savle S, et al. Elastosis perforans serpiginosa associated with pseudo-pseudoxanthoma elasticum during treatment of Wilson's disease with penicillamine. *Dermatology* 2005; 210: 60-3
- Kuhn TS. The structure of scientific revolutions. 2nd ed. Chicago (IL): University of Chicago Press, 1970
- Koo J, Gambla C, Fried R. Pseudopsychodermatologic disease. *Dermatol Clin* 1996; 14: 525-30

Correspondence and offprints: Dr *Raphael B. Stricker*, California Pacific Medical Center, 450 Sutter Street, Suite 1504, San Francisco, CA 94108, USA. E-mail: rstricker@usmamed.com