L'anthropologie 124 (2020) 102797

Available online at www.sciencedirect.com

ScienceDirect

et également disponible sur www.em-consulte.com

Original article

Hibernation in hominins from Atapuerca, Spain half a million years ago☆

Hibernation des hominidés d'Atapuerca, en Espagne, il y a un demi-million d'années

Antonis Bartsiokas [a,*], Juan-Luis Arsuaga [b,c]

[a] *Department of History and Ethnology, Democritus University of Thrace, 69100 Komotini, Greece*
[b] *Centro Mixto Universidad Complutense de Madrid-Instituto de Salud Carlos III de Evolución y Comportamiento Humanos, 28029 Madrid, Spain*
[c] *Departamento de Geodinámica, Estratigrafía y Paleontología, Facultad de Ciencias Geológicas, Universidad Complutense de Madrid, Calle José Antonio Novais 12, 28040 Madrid, Spain*

ARTICLE INFO

Article history:
Available online 27 November 2020

Keywords:
Hibernation
Atapuerca
Chronic Kidney Disease (CKD)
Renal Rickets
Secondary Hyperparathyroidism
Renal Osteodystrophy (ROD)

ABSTRACT

Both animal hibernation and human renal osteodystrophy are characterized by high levels of serum parathyroid hormone. To test the hypothesis of hibernation in an extinct human species, we examined the hominin skeletal collection from Sima de los Huesos, Cave Mayor, Atapuerca, Spain, for evidence of hyperparathyroidism after a thorough review of the literature. We studied the morphology of the fossilized bones by using macrophotography, microscopy, histology and CT scanning. We found trabecular tunneling and osteitis fibrosa, subperiosteal resorption, 'rotten fence post' signs, brown tumours, subperiosteal new bone, chondrocalcinosis, rachitic osteoplaques and empty gaps between them, craniotabes, and beading of ribs mostly in the adolescent population of these hominins. Since many of the above lesions are pathognomonic, these extinct hominins suffered annually from renal rickets, secondary hyperparathyroidism, and renal osteodystrophy associated with Chronic Kidney Disease - Mineral and Bone Disorder (CKD-MBD).

☆ A preliminary report of thispaper has appeared as a preprintin PeerJ: Bartsiokas A & Arsuaga JL 2018. Hibernation, puberty and chronic kidney disease in troglodytes from Spain half a million years ago. PeerJPreprints 6:e27370vl https://doi.org/10.7287/peerj.preprints.27370vl.

* Corresponding author.
E-mail address: bartsiokas.ant@gmail.com (A. Bartsiokas).

https://doi.org/10.1016/j.anthro.2020.102797
0003-5521/© 2020 Elsevier Masson SAS. All rights reserved.

We suggest these diseases were caused by poorly tolerated hibernation in dark cavernous hibernacula. This is particularly evidenced by the rachitic osteoplaques and the gaps between them in some of the adolescent individuals along with the evidence of healing mainly in the adults. The sublayers in the rachitic osteoplaques indicate bouts of arousal from hibernation. The strong projection of the external lip of the femoral trochlea, the rachitic osteoplaques with the empty gaps between them, the "rotten fence post" sign, and the evidence of annual healing also point to the presence of annually intermittent puberty in this extinct human species. The hypothesis of hibernation is consistent with the genetic evidence and the fact that the SH hominins lived during an extreme glaciation. Alternative hypotheses are examined. The present work will provide a new insight into the physiological mechanism of early human metabolism which could help in determining the life histories and physiologies of extinct human species.

© 2020 Elsevier Masson SAS. All rights reserved.

Mots clés :
Hibernation
Atapuerca
Insuffisance rénale chronique (IRC)
Rachitisme rénal
Hyperparathyroïdie secondaire
Ostéodystrophie rénale (ODR)

R É S U M É

Les périodes d'hibernation chez l'animal et l'ostéodystrophie rénale en pathologie humaine sont associées à des taux sériques élevés d'hormone parathyroïdienne. Après une revue approfondie de la littérature, nous avons examiné la collection de squelettes d'hominidés de Sima de los Huesos, Cave Mayor, Atapuerca, Espagne, pour y rechercher des traces d'hypersécrétion parathyroïdienne. L'étude a été réalisée en associant macrophotographie, analyses microscopiques, histologiques et imagerie par tomodensitométrie. Nous avons observé principalement dans la population adolescente de ces homininés des aspects de tunnelisation osseuse trabéculaire, d'ostéite fibreuse, de résorption sous-périostée métaphysaire, de tumeurs brunes, d'ossification sous-périosté, de chondrocalcinose, des ostéophytes disséminés, de craniotabès et de perles costales. Plusieurs de ces lésions sont pathognomoniques et montrent que ces hominines étaient atteints chaque année d'ostéomalacie, d'hyperparathyroïdie secondaire et d'ostéodystrophie rénale. Nous estimons que ces troubles sont consécutifs à une hibernation dans des grottes sombres. Ceci est particulièrement mis en évidence par la présence de plaques osseuses rachitiques disséminées chez certains des adolescents, et de lésions cicatrisées principalement chez les adultes. Les sous-couches dans les plaques osseuses rachitiques indiquent des épisodes de suractivité liée à l'hibernation. La forte saillie de la lèvre externe de la trochlée fémorale, les plaques osseuses rachitiques séparées par des zones normales, les zones de résorption sous-périostée et les preuves de guérison annuelle indiquent également la présence d'une puberté intermittente chaque année chez cette espèce humaine disparue. Notre hypothèse rattachant ces lésions osseuses aux conséquences de l'hibernation est cohérente avec les arguments génétiques et le fait que les hominidés de SH ont vécu pendant une glaciation extrême. Des hypothèses alternatives sont examinées. Le présent travail apporte une approche novatrice des mécanismes physiologique du métabolisme des premiers humains qui pourrait aider à déterminer le cycle de vie et la physiologie des espèces humaines éteintes.

© 2020 Elsevier Masson SAS. Tous droits réservés.

1. Abbreviations

ROD	Renal Osteodystrophy
PTH	Parathyroid Hormone
2HPT	Secondary Hyperparathyroidism
1HPT	Primary Hyperparathyroidism
OF	Osteitis Fibrosa Cystica
OM	Osteomalacia
SH	Sima de los Huesos
LD	Lamina dura
CKD-MBD	Chronic Kidney Disease - Mineral and Bone Disorder
BT	Brown Tumor
BAT	Brown Adipose Tissue
BeAT	Beige Adipose Tissue
GI	Gastrointestinal
PNB	Subperiosteal new bone
SPR	Subperiosteal resorption
ROP	Rachitic Osteoplaque
CPPD	Calcium pyrophosphate dihydrate disease
HZAG	Hibernational Zone of Arrested Growth

2. Introduction

It was observed that serum 5′-AMP is elevated in dark-dark mice (Lee, 2007). This led many researchers to inject it in human subjects and experimental animals. The results showed that hibernation is possible in humans as inducing a hypometabolic state analogous to hibernation (Blackstone et al., 2005; Lee, 2008; Wang, 2010; Hashimoto, 2006). Similarly, synthetic 5′-AMP induces hypothermia and torpor when injected into non-hibernators such as light-dark mice (Zhang et al., 2006; Lee, 2007) and activates procolipase expression, all key features of hibernating mammals (Lee, 2007). Their experiments show that under certain circumstances non-hibernators such as humans can hibernate. In addition, many adult and non-adult humans have Beige Adipose Tissue (BeAT, Wu et al., 2012) and/or Brown Adipose Tissue (BAT, van Marken Lichtenbelt et al., 2009), a tissue used by hibernators during arousals from hibernation bouts (Nedergaard and Cannon, 1990) (see also 6.3).

Both animal hibernation and human renal osteodystrophy (ROD) are characterized by high parathyroid hormone (PTH, McGee-Lawrence, 2008; Weller, 1968). To test whether there is hibernation in extinct humans we searched for pathognomonic evidence of metabolic diseases and diagnostic effects of hibernation in their skeletal material. To this end, we studied the enormous hominin skeletal collection from Sima de los Huesos ("Pit of bones" known as "SH"), Cave Mayor, Atapuerca. The SH site is a deep shaft in the Cave Mayor of Sierra de Atapuerca (Spain) with thousands of fossil hominin bones (at least 7500) belonging to at least 29 individuals (Arsuaga et al., 2014; Bermúdez de Castro et al., 2020). They have an age of 448 ± 15ka (Demuro, 2019) and they belong to a stem group for Neanderthals and modern humans (Arsuaga et al., 2014; Homo heidelbergensis?). The site can be regarded as a mass grave in the sense that it is a place of deliberate disposal of multiple dead (Sala et al., 2015; Arsuaga et al., 2015). The bones are disarticulated and commingled but were deposited during the same sedimentation period (Bermudez de Castro et al., 2003). The SH cranial sample is morphologically quite homogeneous (Arsuaga et al., 2014; Bermudez de Castro et al., 2003).

Lithostratigraphy. The SH site is a talus cone made of pliable clay at the bottom of a shaft 500 meters from the current entrance of Cave Mayor. At the time of the bone deposition the cave entrance was above the shaft. There is only one hominin/bear fossil horizon (LU-6) preserved at SH. Then, this provokes the question "since the bears were hibernating, why not the humans?" The length of time the site was in use by the hominins is not known since the range of the mean values of the dates obtained are in the order of several thousands years (Arsuaga et al., 2014).

Chronology. The excavators (Arsuaga et al., 2014) have provided a thorough review of dates obtained from a suite of numerical and relative dating methods including Uranium series (U-series) dating of speleothems, thermally transferred optically stimulated luminescence (TT-OSL) dating of quartz and post-infrared infrared stimulated luminescence (pIR-IR) dating of sedimentary quartz and K-feldspar grains, paleomagnetism, electron spin resonance (ESR) dating of quartz, combined ESR/U-series dating of bear teeth, genetic age estimates from one hominin and one *Ursus deningeri* mtDNA, and biostratigraphy. A U-series dating of a speleothem attached to a hominin cranium (cranium 4) yielded a mean age of 434 +36/−24 ka (Arsuaga et al., 2014). Dates from most of the above techniques center around 448,000 years ago.

We present a histologic, paleopathologic, and ontogenetic analysis of the SH hominins and their effects on the physiology of this species. Results herein emphasize the possibilities for derivation of growth patterns from bone microstructure and pathology of extinct human species, and elucidate important aspects of the life history strategies employed by an extinct human species (see below e.g. 5.3). The present work will provide a new insight into the physiological mechanism of early human metabolism during hibernation which could help not only in determining the life histories, growth and physiologies of extinct human species, but could also have profound implications for understanding the pathophysiological basis of various diseases (Breukelen and Martin, 2002) and cryomedicine. We have investigated and presented for the first time a spectrum of pathognomonic features of chronic kidney disease (CKD) in specimens of *Homo heidelbergensis* recovered in Atapuerca of Spain. This is a description of an extinct human population with skeletal markers of a disease consistent with poorly tolerated hibernation. A preliminary report of this hypothesis has been presented earlier as a preprint (Bartsiokas and Arsuaga, 2018).

2.1. The effects of hibernation on bone

Winter hibernation is best regarded as a physiologic adaptation to anticipated famine that involves a decrease in metabolic rate and body temperature in a niche of constant darkness (McGee-Lawrence et al., 2008; Hock, 1960; Cizza et al., 2004; Zhang, 2006; Lee, 2007). Torpor is the reduction of body temperature and metabolic rate for less than 24 h and hibernation occurs when the torpor phases are longer than 24 h up to several months. In nearly all hibernators, torpor is interrupted by bouts of arousal (Pengelley and Fisher, 1961; Geiser, 1995). Because the decrease in metabolic rate, body temperature, and heart rate was not possible to measure in this human population, we tried to find evidence for cessation of food intake and bouts of arousal in the bone collection. It should be noted that here we studied an extinct human species and a fossilized population with no soft tissues preserved. So, our diagnoses of the lesions and hibernation relied mainly on bone histological characteristics. Thus, it was not possible to measure parameters such as fat content, PTH, and other blood parameters to determine the levels of prehibernating fattening and the stress that followed but their presence is deduced by the lesions they caused.

Four are the main skeletal effects to diagnose normal and/or poorly tolerated hibernation in many animal hibernators: the lines of arrested growth due to hibernational famine, the resorption effects due to PTH, the healing effects during the post hibernation period and the adolescent mortality distribution. All of them are present in the SH population as we show below.

The lines of arrested growth. Cortical bone deposition can be temporarily slowed or halted in response to annual rhythms in living and extinct poikilothermic and homeothermic tetrapods, resulting in compact bone being interrupted by dense growth marks (Turvey et al., 2005; Bybee et al., 2006). They are all skeletochronological indicators that may reflect cyclical annual growth, or other endogenous rhythms (Padian et al., 2001) as suggested by their occurrence in extant crocodilians,

some rodents and polar bears (Ray et al., 2005). The broad laminae in compact bone such as the rachitic osteoplaques, are formed annually only in vertebrates that undergo periods of hibernation (Chinsamy et al., 1998). Rickets is caused primarily by a deficiency of fat as fat is rich in vitamin D (Mawer et al., 1972; Vestergaard et al., 2011) that is released during lipolysis. The lines of arrested growth may appear in other stress situations but they are more distinct in hibernators (Cool et al., 1994). These lines are due to osteoid deposition during hibernation, lack of Ca (Suzuki, 1963) and decreases in the secretion of growth hormone in severe cold (Donahue et al., 2006; Pääkkönen and Leppäluoto, 2002). If they do not calcify they form gaps as here. They may also be deposited endosteally in the short posthibernation phase (Whalen et al., 1972) due to increased calcitonin to inhibit lipolysis forming an osteoid layer made of collagen that later calcifies into lines of arrested growth (Kwiecinski et al., 1987). They are more distinct when animals are submitted to contrasting climates during the annual cycle e.g., in populations in high altitudes or latitudes (Castanet and Baez, 1991; Turvey et al., 2005) especially if they are interrupted by empty gaps. In case they present sublayers, these are evidence of interbout arousals, which are unique to hibernation. We found here in SH this evidence of hibernation bouts of arousals from their effects, i.e., bone growth arrest and sublayers of the rachitic osteoplaques. These effects are diagnostic of hibernation.

The resorption effects include features such as osteocytic osteolysis, Osteitis Fibrosa Cystica (OF, i.e., tunneling resorption in the trabeculae), peritrabecular fibrosis (osteoclastic resorption), subperiosteal resorption, brown tumors, loss of lamina dura, and "rotten fence post" signs in various animals. Apart from osteocytic osteolysis, the rest of the resorption effects are not diagnostic of hibernation but are consistent with this.

The healing is deduced from the presence of brown tumors, periosteal new bone, and extensive enlargement of the Haversian canals. None of them is diagnostic of hibernation but are consistent with this.

The adolescent mortality distribution is the result of famine during hibernation and is unique to hibernation. For instance, the bear juvenile-dominated population structure in the Mokrica cave (Slovenia) and other caves is characteristic of hibernation-related mortality in typical cave bear sites. The majority of their deaths occurred during hibernation or in short posthibernation period mainly because of starvation (Debeljak, 2007; Krajcarz et al., 2014) due to inadequate fat reserves. Starvation is the main reason of mortality in hibernating bears and especially their cubs (Krajcarz et al., 2014).

We have to emphasize that hibernations are not always healthy as happens nowadays in many starving polar bears. There are cases where all of fat and vitamin D stores are depleted resulting in CKD and its associated pathologies. The adults in SH of course underwent hibernation too but they did not show any pathologies — only the healing effects of it — as they didn't have so great energy demands as the adolescents. Here, are some examples of the ill effects of poorly tolerated hibernation in seasonal hibernators described so far:

The case of Dragon's Cave of Mixnitz in Austria where the remains of the cave bear *Ursus ingressus* belong to individuals that died during hibernation as they developed various pathologies including rickets, kyphosis, and OF because they were unable to build up a sufficient store of fat (Breuer, 1931; Kurten, 1969). OF is actually not reported by Breuer (1931) but is shown in a trabecular bone section in his Fig. 2 of Taf. XCII, misidentified as vascular gaps. Many cases of rickets and ostemalacia have also been reported in fossil bears (Wells, 1975). Black bears that die during hibernation are uremic (Nelson et al., 1983). McGee-Lawrence et al. (2008) have noticed that the impairment of renal function in hibernating bears is similar to that of humans with renal failure in that the glomerular filtration rate decreases in both species. Indeed, in small hibernators and American black bears there is reduction or cessation of the glomerular filtration rate (Zancanaro et al., 1999; Brown et al., 1971; Hong, 1956) experienced during a hibernation bout (Hittel and Storey, 2002). Small hibernating mammals such as bats (Whalen et al., 1972; Nunez and Gerzhon, 1972), hamsters (Steinberg et al., 1981) and ground squirrels experience PTH-induced OF (McGee-Lawrence et al., 2008). In the little brown bat, *Myotis lucifugus lucifugus*, a marked hyperparathyroidism (HPT) existed during hibernation (Kwiecinski et al., 1987). In hibernating woodchucks, the increased secretion of Adrenocorticotropic Hormone (ACTH) may play a role in the genesis of renal glomerular disease which is an important cause of mortality (Christian et al., 1965). Cortisol levels are increased under the stimulation of ACTH during hibernation as well as in 2HPT in order to aid in fat catabolism. Excessive secretion of cortisol may explain

proteinuria in the hibernating dormouse *Muscardinus avellanarius* (Zancanaro et al., 1999), uremia in black bears (Nelson et al., 1983) and death in the hibernating mouse lemur *Microcebus murinus* from chronic glomerulonephritis (Perret and Predine, 1984). Therefore, hibernators may suffer from rickets, HPT, and OF if they do not possess sufficient fat reserves. These diseases are all expressions of ROD consistent with CKD-MBD.

2.2. How a human population like that of SH might have resorted to hibernation

Although hibernators are capable of reaching physiological states that would be lethal to modern humans, various degrees of hypometabolism and hypothermia might have been tolerated by the latter (Carey et al., 2003). For instance, in circum polar humans there is ethnographic and historical evidence about a type of hypometabolism called *Lotska* in Russian famine areas of Pskov (east of Latvia) which is saving energy and warmth in an 'almost uninterrupted sleep' for six months that is analogous to hibernation (Dirks, 1980). Perhaps it is the same state mentioned since ancient times by the father of history, Herodotus, for people living north of Scythia (i.e., today's Russia) 'who sleep for half a year' (Dirks, 1980) which is reminiscent of ursine hibernation, a state similar to prolonged sleep (Seger et al., 2011).

The notion that humans can undergo a hypometabolic state analogous to hibernation may sound like science fiction but the fact that hibernation is used by very primitive mammals (placentals, marsupials, monotremes) and primates (bushbabies, lorises, dwarf and mouse lemurs; Blanco et al., 2018) suggests that the genetic basis and physiology for such a hypometabolism could be preserved in many mammalian species including humans (Lee, 2007; 2008) since all mammals share the basic genetic mechanism (i.e., hardware) of heterothermy (Blanco et al., 2018). BAT and beige fat (BeAT) in modern humans are consistent with this hypothesis as they are important in all phases of hibernation and especially in arousal from it (Blackstone et al., 2005; Lee, 2008). Thus, hibernation may have been part of our primate predecessor's life history (Schulke and Ostner, 2007; Blanco et al., 2018). Hence, the prospect of existence of a hypometabolic state akin to hibernation in extinct human species may seem more realistic now than it has been so far (Breukelen and Martin, 2002).

There is also an evolutionary ground for it: gradual cooling during the Middle and Late Miocene in the then subtropical Europe, led hominoids (apes) to wide-spread starvation during winter due to food scarcity. The global cooling continued and around 16 million years ago (Ma), a mutation in uricase gene, that converts fructose into fat, enabled them to survive winter famines by becoming fat (Johnson and Andrews, 2015). The loss of uricase activity led to the increased uric acid in hominoids (Alvarez-Lario and Macarrón-Vicente, 2001). This resulted in hyperuricemia (Alvarez-Lario and Macarrón-Vicente, 2001), which is associated with fat accumulation (Tsushima et al., 2013). The cooling led to the Valesian crisis (9 Ma ago) when most of European apes became extinct or migrated back to Africa and evolved into African apes and humans that carried the mutation in uricase gene to hominins and modern humans (Johnson and Andrews, 2015). The cooling also stimulated the secretion of cortisol from the adrenal gland to increase thermogenesis by activating the mitochondria of BAT and WAT (Pääkkönen and Leppäluoto, 2002; Dembert, 1982). Cortisol is a stress hormone (glucocorticoid), produced by the adrenal gland that decreases bone formation (Donahue et al., 2003) and increases collagen synthesis (Rosen and Luben, 1983) and bone resorption (Donahue et al., 2003). Cortisol's primary functions are to aid in lipolysis (Hoehn and Marieb, 2010). Hypercortisolism is a condition known to induce bone loss by inhibiting bone formation (Donahue et al., 2003; Ducy et al., 2000). Since elevated glucocorticoids (cortisol) are necessary for the energetic requirements of hibernation (Gustafson and Belt, 1981), there might have been adaptations that could have enabled some hominoids and hominins to survive famines and harsh winters during glaciations as here in SH by storing body fat and using it during hibernation with all of its ill effects.

Indeed, in hibernators, there is increased mitochondrial activity to prevent widespread cellular damage caused by the cold and ischemia experienced during a hibernation bout (Hittel and Storey, 2002). During early hibernation, large cytoplasmic lipid-mitochondria complexes are formed in the parathyroid gland, reflecting a high degree of fat utilization to provide the energy required for the synthesis of PTH (Nunez et al., 1971). Cortisol, inhibits calcium absorption in the intestine which

probably results in 2HPT (Raisz, 1984). Cortisol and PTH increase significantly whereas growth factor IGF-I decreases during hibernation of black bears (Donahue et al., 2006; Pääkkönen and Leppäluoto, 2002). Similarly, in the hibernating bat, *Myotis lucifugus lucifugus,* the adrenal cortex is highly active during hibernation producing high levels of plasma cortisol which have an annual rhythm (Gustafson and Belt, 1981) and would be necessary for the energetic requirements of hibernation (Gustafson and Belt, 1981) by aiding in lipolysis. The hibernating dormouse *Muscardinus avellanarius* has an active glomerular zone in the adrenal gland too (Zancanaro et al., 1999). Some males in the hibernating mouse lemur *Microcebus murinus* develop hypercortisolism and die of chronic (glomerulo)nephritis (Donahue et al., 2003) consistent with 2HPT and ROD pathology in hibernation. Its cortisol levels remain elevated during darkness in the hibernation phase and decrease significantly under long daylength, during the activity period (Donahue et al., 2003).

These adaptations seem to have survived till recently. For instance, Inuit populations along with some Siberians possess two genes, TBX15 and WARS2, associated with cold tolerance. They are thought to cause the formation of brown fat (BAT) and the efficient use of oxygen when the air is thin at high altitudes. These genes are close to the genes found in the fossil populations of Denisovans (*H. sapiens denisova*?) and have been associated with the activation of the adrenal gland and BAT in humans (Racimo et al., 2017) as in hibernation. The variant of these genes was likely introgressed from archaic humans living in Eurasia at least 20 thousands years ago (Racimo et al., 2017). As regards the mitochondrial DNA (which is activated during hibernation), the SH hominins are genetically closely related to Denisovans (Meyer et al., 2014) who were adapted to high altitude and cold (Huerta-Sánchez et al., 2014; Racimo et al., 2017). It comes to no surprise that the SH hominins lived in an extreme glacial period and their cave is at an elevation of about 1000 masl, i.e., about 300 m higher than that of the Denisova cave (see also 5.1).

Thus, the adrenal glands are hyperactive during hibernation producing high levels cortisol that can cause lipolysis, bone loss and collagen formation leading to HPT and acquired (glomerular) type of ROD. So, the SH hominins might well have had adaptations akin to cold and hibernation as closely related to Denisovans by living in high altitude caves during glacier times causing some of them to acquire pathologies of poorly tolerated hibernation. These pathologies and lesions are presented below in the Results and Discussion.

2.2.1. Renal Osteodystrophy (ROD) and CKD-Mineral and Bone Disorder (CKD-MBD)

The term ROD refers collectively to the various osseous abnormalities associated with chronic kidney disease (CKD) and defined by bone histomorphometry (Ketteler et al., 2018; Moe et al., 2006). CKD-MBD a common complication of CKD caused by abnormalities in Ca, increased serum phosphate, PTH, Vitamin D, bone turnover, growth, and soft tissue calcification (Ketteler et al., 2018; Moe et al., 2006; Webster et al., 2017). As CKD progresses, vitamin D deficiency increases and results in hypocalcemia and 2HPT (Webster et al., 2017).

ROD may be divided into acquired (glomerular) and congenital (tubular) type (Weller et al., 1968). Acquired type of ROD is due to functional renal impairment (Weller et al., 1968) and in humans can occur in cases of protein malnutrition or prolonged immobilization (Pitt, 1988). It consists of a mixture of OF (i.e., tunneling trabeculae, osteoclastic resorption and PNB), 2HPT, rickets or osteomalacia, and growth retardation, with a biochemical picture of hypocalcemia, hyperphosphatemia, and vitamin D deficiency (Schwartz et al., 1977; Pitt, 1988; Olmastroni et al., 1997). OF is by far more common in the acquired type of ROD than the congenital one (Weller et al., 1968). Vitamin D deficiency induces hypocalcemia which in turn induces 2HPT. Untreated 2HPT leads to ROD.

2.2.2. Hyperplastic or Hypertrophic rickets

In subjects with vitamin D deficiency which are otherwise well nourished, a hypertrophic form of rickets develops. In this case, bone cortices are thick because of exuberant deposition of wide concentric layers of osteoid by the periosteum and medullary cavities stenosed (Pezeshk and Carrino, 2009; Meredith et al., 1978). That is not to imply that the robusticity and the stenosis of the SH bones is due solely to such hypertrophy, but it may explain the absence of some signs of rickets in the SH collection (see also 6.1).

3. Materials and Methods

We used most of the *Sima de los Huesos* (SH) enormous collection of fossilized bones. SH has been excavated since 1983 with every year producing more human fossils. So far, more than 7,500 fossil human skeletal remains have been found. A large number of them were inspected and sorted out regarding the presence of any metabolic diseases. Only a few of them have been presented here with the most interesting and representative lesions (Table 1). No quantitative data can be presented as it is not known which element belongs to which individual and of what exactly biological age. Quantitative assessment was possible to be done only on the crania (Table 2) that were better documented. The published lesions so far are mainly traumata (Sala et al., 2015).

The sediment, the bones were deposited in, is soft plastic clay due to the moisture of the cave. So, it has not affected the surface of the bones and consequently has not affected the surface lesions at all.

The investigation is primarily based on macroscopical techniques such as macrophotography, histology and CT scanning as well as microscopy. The diagnosis is based on a morphoscopical inspection of a magnified area. Bones were first examined under normal lighting conditions and a series of magnifying glasses ranging in magnification from 2X to 40X starting from the low magnifications to identify the possible lesions. A binocular Nikon SMZ800 stereozoom microscope with table stand and 10X widefield eyepieces with a camera attached was used subsequently in several occasions. It had a continuous zoom range magnification from 10X to 63X. For

Table 1
The lesions identified in SH and approximate biological ages of the specimens.

Specimen and code number	Estimated age at death	Pathologies
Scapula ESC X Scapula AT-1151	Adolescent	Osteitis Fibrosa (intratrabecular tunneling, peritrabecular fibrosis)
Scapula AT-2563+ AT-2471	Adolescent	Peripheral ridge in the glenoid cavity
Cranium 9	Adolescent	Rachitic Hyperostosis with rachitic osteoplaques and gaps between them, craniotabes with intratrabecular tunneling. Lamina Dura
Radius AT-4216	Adolescent	Lines (zones) of arrested growth with gaps between them
Femur AT-2240 + AT-2118 + AT208	Adolescent	Intense development of Osteitis Fibrosa (OF) ("Rotten fence post" sign) in the femoral necks
Femur F3	Early Adolescent	Minor development of Osteitis Fibrosa (OF) ("Rotten fence post" sign) in the femoral necks
Femur F5	Adult	No Osteitis Fibrosa ("Rotten fence post" sign) in the femoral neck
Pelvis 1	Adult	Brown tumours, CKD, Resorption in the symphysis pubis
Distal fibula AT886 + AT1252	Adolescent	Osteitis Fibrosa ("Rotten fence post" sign, subperiosteal resorption, metaphyseal cupping and frayed margins), renal rickets, 2HPT
Vertebra VC18	Adolescent	CPPD (chondrocalcinosis in annulus fibrosus), lipolysis of BAT during interbout arousals from hibernation
Ribs AT-3030, AT-1241, and AT-2996 + AT-3067		beading (i.e., rachitic rosary) or "rotten fence post" sign in 2HPT and renal rickets
Tibia II	Adolescent	Scalloping subperiosteal resorption in ROD
Tibia III	Adult	Largely healed. Only sparse porosity remains
Phalanges AT-2520 and AT- 2521		Subperiosteal or phalangeal resorption pathognomonic of severe chronic 2HPT and CKD
Left middle phalanx 5 (AT-1304)	Adult	Periosteal new bone
Middle hand phalanx 3 or 4 (AT-3154)	subadult	Periosteal new bone
AT-98 distal phalanx of foot		Acro-osteolysis of distal phalange (resorption of the terminal tufts), Osteitis Fibrosa (intratrabecular tunneling)
Cranium 14	Adolescent	Craniosynostosis consistent with rickets
Cranium 3	Adolescent	Subperiosteal new bone around the parietal eminences. It may be a remnant of craniotabes
Humerus AT-742	Adult	Subperiosteal new bone

Table 2
The adolescent crania and their pathologies. The biological ages are after Arsuaga et al. (2014) [their Table S1].

Specimen of cranium	Age at death	Pathology
Cranium 3	Adolescent	Periosteal new bone around parietal eminence indicating healed craniotabes of rickets
Cranium 6	Adolescent	Non-pathologic
Cranium 9	Adolescent	Rachitic hyperostosis supraorbitally indicating rickets
Cranium 11	Adolescent	Non-pathologic
Cranium 14	Adolescent	Craniosynostosis consistent with rickets

macrophotography, a macro lens was attached to the camera. The method has been described elsewhere (Bartsiokas, 2000). Histology is not a "thin cross section-histology" because invasive techniques were not allowed. We used only naturally broken bulk sections of bones to study the internal morphology and histology. Bone histology is the only secure means to identify diseases pathognomonically in skeletal material since blood sampling is not possible. It provides valuable information on aspects of a human's life such as growth, pathology, biomechanics, and lifestyle when histological integrity is generally maintained after fossilization. It is a more sensitive test than radiography for the presence of bone diseases such as renal osteodystrophy (ROD; Hsu et al., 1982). The science of paleopathology relies mainly on bone histology and bone external morphology to obtain diagnosis. The Pelvis 1 was scanned at the University of Burgos (Spain) using an YXLON MU2000-CTscanner with scanner energy 120 kV and 150 mA and slide thickness 0.5 mm. Osteocyte lacunae were not preserved but the rest of the microstructures such as trabeculae and Haversian canals are in a good state of preservation to allow the methods we used. The identification of the diseases was based on medical and paleopathological literature.

4. Results and Discussion

The results are summarized in Tables 1 and 2, and Figs. 1–18. A detail description and identification of the lesions follows.

4.1. Osteitis Fibrosa (OF)

Initially, we used the ultimate criterion for bone diagnosis, that of histology (Hsu et al., 1982). Fig. 1 shows the spongiosa from a natural fracture of Scapula ESC X, which belonged to an adolescent. It can be seen that some of the trabeculae are hollowed out by minute tunnels. The histological hallmark of 2HPT identification is osteitis fibrosa (OF; Slatopolsky and Delmez, 1998; Vigorita, 1999). OF is an intratrabecular osteoclastic tunneling resorption (Vigorita et al., 1986) called also dissecting osteitis secondary to high levels of PTH. The tunneling in Fig. 1 fits perfectly the above description of OF and is an indisputable pathognomonic evidence of OF in our sample. Scapula AT-1151 also presents such OF.

OF also refers to increased resorption on trabecular surfaces called peritrabecular fibrosis (Resnick and Niwayama, 1995a,b) or 'cookie-bite defects' (Mays et al., 2007) which is an osteoclastic resorption evidenced by numerous Howship's (resorption) lacunae covering the trabecular surface. In thin sections it forms an undulating front containing numerous resorption lacunae (Adler, 2000). Such minute depressions (i.e., Howship's lacunae) are shown in scapulae AT-1151 and ESC X too (Fig. 2) in great numbers. They have a brownish coloration due to the clay of the cave deposited in them postmortem and fit perfectly the description of peritrabecular fibrosis. Because these lesions are formed as residua in treated patients with secondary hyperparathyroidism (2HPT; Vigorita et al., 1987), we infer that these lesions in the aforementioned scapulae are similarly residues of 2HPT in a post-hibernation phase.

Other histological features of OF include trabeculae of varying width, intertrabecular spaces of various sizes (Adler, 2000) and short and thin bony spicules transversal to the trabeculae. Some of these spicules can also be seen in Fig. 1.

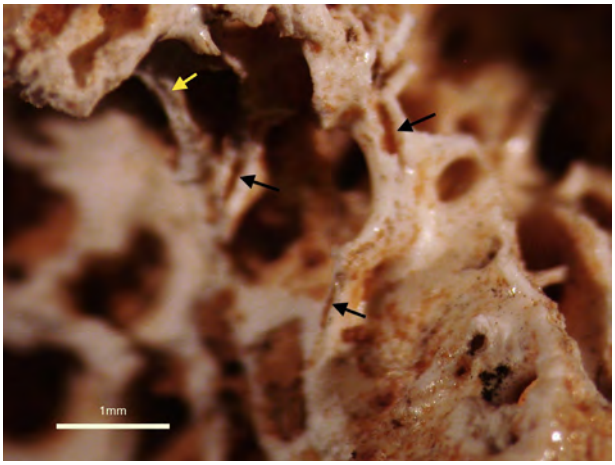

Fig. 1. Histology of scapula ESC X. Natural fracture of scapula ESC X in the area where the spine meets the body of the scapula. It shows tunneling resorption forming intraosseous cavities in the trabeculae (arrows), which is conclusive evidence of osteitis fibrosa (OF). Some of the trabeculae are unfocused because this is a natural bulk section. These tunnels are the residua of active zones of osteoclastic tunneling resorption due to secondary hyperparathyroidism (2HPT). Note also numerous brown depressions (peritrabecular fibrosis) on the surface of the trabeculae (also in Fig. 2) and thin bony spicules transversal to the trabeculae caused by OF too (Adler, 2000).

Coupe histologique de la scapula ESC X. Fracture naturelle dans la zone médiale de la scapula. Elle montre la présence d'une résorption en tunnel ayant créé des cavités dans l'os trabéculaire caractéristiques d'ostéite fibreuse (flèche). Certaines trabécules ne sont pas nettement visibles en raison de la fracturation naturelle. Ces tunnels sont les résidus de zones actives de résorption ostéoclastique par hyperparathyroïdie secondaire (2HPT). On note la présence de nombreuses dépressions brunes (fibrose péritrabéculaire) à la surface des trabécules (également sur la Fig. 2) et de minces spicules osseuses perpendiculaires aux trabécules provoqués également par l'ostéite fibreuse (OF) (Adler, 2000).



Fig. 2. Scapula ESC X showing OF. Natural fracture of scapula ESC X showing OF in the form of peritrabecular fibrosis in the spongiosa. The trabecular surfaces are covered by numerous minute depressions of brownish staining due to diagenetic clay deposited in them postmortem. They are caused by osteoclastic resorption and they are leftovers of active 2HPT in the SH hominins.

Scapula ESC X présentant une OF. Fracture naturelle de la scapula ESC X montrant une OF sous forme de fibrose péritrabéculaire dans l'os spongieux. Les surfaces trabéculaires sont couvertes par de nombreuses et très petites dépressions de coloration brunâtre dues à l'argile diagénétique déposée post-mortem. Elles résultent de la résorption ostéoclastique et sont des séquelles de 2HPT actif chez les hominines de SH.

Fig. 3. Rachitic hyperostosis. A: Cranium 11 (a juvenile). B: Cranium 9 (adolescent). C: Cranium 4 (adult). Note the fine porosity on the Cranium 9 supraorbital area caused by excessive deposition of new bone (arrow) which is absent in the other crania. This is typical rachitic hyperostosis with a typical 'cardboard-like bone' surface. In either side of Cranium 9, are the calvaria of a younger (left) and an older (right) individual from SH to demonstrate the absence of rachitic hyperostosis in them as the Cranium 9 is apparently in growth spurt: in older or younger individuals where growth and rickets are less active, the cross section of the cranial bone has a normal histology. The angular appearance of Cranium 9 is due to the rickety craniotabes.
Hyperostose rachitique. R : Crâne 11 (juvénile). B : Crâne 9 (adolescent). C : Crâne 4 (adulte). On remarque la fine porosité sur la zone supraorbitaire du Crâne 9 causée par un dépôt important d'os néoformé (flèche) qui est absent sur l'autre crâne. Il s'agit d'une hyperostose rachitique typique avec une surface osseuse décrite classiquement comme d'aspect cartonneux. De chaque côté du Crâne 9 se trouvent les temporaux d'un individu plus jeune (à gauche) et plus âgé (à droite) de SH pour montrer l'absence de lésions d'hyperostose rachitique sur eux. Le Crâne 9 est apparemment en poussée de croissance; chez les individus plus âgés ou chez de plus jeunes quand la croissance et le rachitisme ont été moins actifs, l'aspect histologique de la section transversale des os du crâne est normale. L'aspect anguleux du Crâne 9 est dû aux craniotabes du rachitisme.

Fig. 4. Rachitic hyperostosis. Close up of the rachitic hyperostosis of Cranium 9. To the left, the last hibernational gap (HZAG) has been revealed because the last rachitic hyperostosis has been detached postmortem.
Hyperostose rachitique. Détail de l'hyperostose rachitique du crâne 9. À gauche, le dernier trou d'hibernation (HZAG) a été mis au jour par le détachement post-mortem de la dernière lésion d'hyperostose rachitique.

4.2. Rachitic Hyperostosis

Cranial bones. In the adolescent (Arsuaga et al., 2014) Cranium 9 there is excessive deposition of new porous bone on the external table of the supraorbital area with fine porosity (Figs. 3–5). It is limited to the outer table whereas the inner table is normal. The diploic trabeculae are thick and coarse with small marrow cavities i.e., there is absence of diploic hyperplasia. A natural cross section in the area above the left orbit shows 4 layers of bone deposition (Fig. 5). These distinct layers are not in firm



Fig. 5. Cross section from above the left orbit of Cranium 9. A natural cross section from the area above the left orbit of Cranium 9 shows 4 rachitic osteoplaques (ROPs) of rachitic hyperostosis (one rachitic osteoplaque is indicated by the star) that are evidence of intermittent (seasonal) adolescent growth spurt due to 4 annual hibernations. The rachitic osteoplaques are separated by hibernational gaps (HZAGs). Note the superficial rachitic osteoplaque is comprised of 4 sublayers which correspond to 4 interbout arousals from torpor indicating that hibernation may have lasted at least 4 months. Scale bar 5 mm.
Coupe transversale au-dessus de l'orbite gauche du crâne 9. Cette section transversale naturelle de la zone sus-orbitaire gauche du crâne 9 montre la présence de 4 plaques osseuses rachitiques (ROP) d'hyperostose rachitique (une plaque osseuse rachitique est indiquée par une étoile) qui sont des traces de poussées de croissance saisonnières des adolescents dues à 4 hibernations. Les plaques osseuses rachitiques sont séparées par des trous d'hibernation (HZAG). Notez que la plaque osseuse rachitique superficielle est composée de 4 sous-couches qui correspondent à 4 réveils post-hibernation indiquant que celle-ci peut avoir duré au moins 4 mois (Échelle : 5 mm).

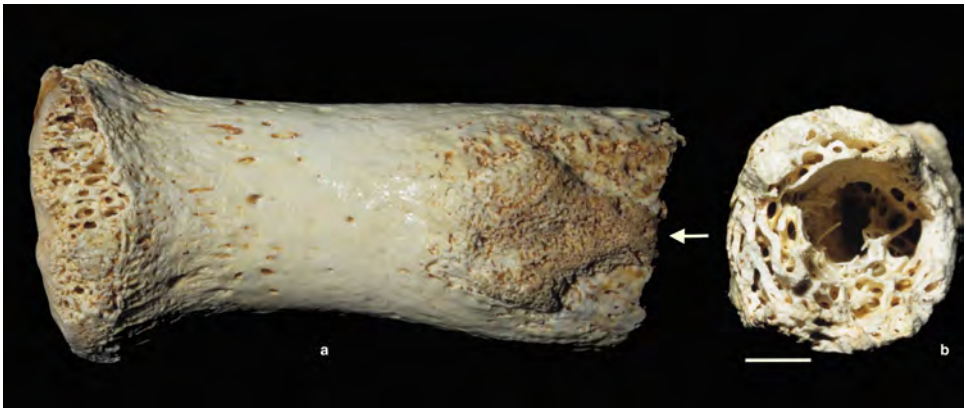

Fig. 6. Radius AT-4216 (a) and its natural cross section (b) at the level of radial tuberosity. The flake epiphysis for tuberosity, indicated by an arrow, shows that it was in puberty. Note at least 4 annual layers of bone. In the adult radii of SH, the layers have been remodeled and therefore are not discernible. The number of layers ties with the fact that the flake epiphysis of the radial tuberosity appears and fuses in puberty that lasts 4 years in modern humans. Scale bar 3 mm.
Radius AT-4216 (a) et sa section (b) au niveau de la tubérosité radiale. L'épiphyse fracturée de la tubérosité, indiquée par une flèche, montre que l'individu avait atteint la puberté. On observe au moins 4 couches d'os annuelles. Sur les radius d'adultes de SH, les couches ont été remodelées et ne sont donc pas discernables. Le nombre de couches est lié au fait que l'épiphyse de la tubérosité radiale apparaît et fusionne à la puberté laquelle dure 4 ans chez l'homme moderne (Échelle 3 mm).

contact between each other but are sharply divided by parallel undulating empty gaps. The superficial layer is comprised of 4 sublayers (Fig. 5).

This porous bone lesion is typical of rachitic hyperostosis (Caffey, 1978). It has been variously termed as "tabetic patch", or "pumice stone-like" skull (Adler, 2000) or "cardboard-like" bone surface.



Fig. 7. Cranium 9. Note the flattening of the parietals giving a squared appearance to the skull known as craniotabes (cf. Fig. 3) or *caput quadratum* (upper left and upper right) that is the clinical hallmark of rickets. Scale bar 5 cm.
Crâne 9. Notez l'aplatissement des pariétaux donnant un aspect carré au crâne appelé craniotabes (cf. Fig. 3) ou caput quadratum (en haut à gauche et en haut à droite) qui est un signe clinique du rachitisme (Échelle 5 cm).



Fig. 8. Cross section of the right parietal of Cranium 9. Natural cross section of the right parietal of Cranium 9 close to the parietal eminence. Note the tunneling (OF) of the diploic trabeculae (arrows) in many areas of the section due to the development of craniotabes in renal rickets. This is evidence of Vitamin D induced 2HPT. Scale bar 4 mm.
Coupe transversale du pariétal droit du crâne 9. Coupe naturelle du pariétal droit du crâne 9 près de la bosse pariétale. Notez la forme de tunnel (OF) des trabécules diploïques (flèches) dans de nombreuses zones de la coupe en raison du développement de craniotabes dans le rachitisme rénal. Ceci est la preuve du 2HPT induit par la vitamine D (Échelle 4 mm).

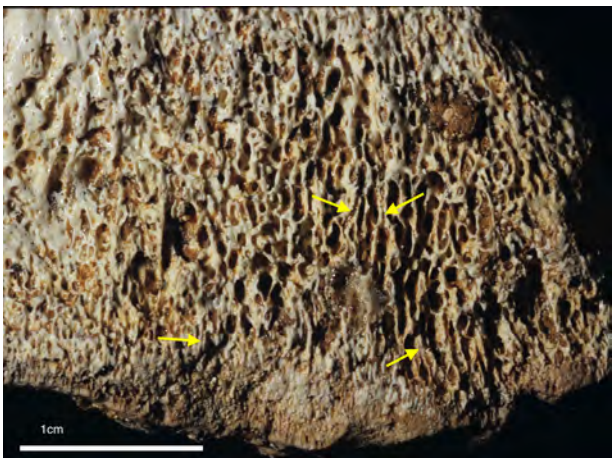

Fig. 9. Metaphysis of the distal femur AT-2240 + AT-2118 + AT208. Note the 'rotten fence post' sign. Some of the trabeculae show tunneling, evidence of OF (yellow arrows).
Métaphyse distale de fémur AT-2240 + AT-2118 + AT208. Notez l'aspect d'érosion sous-périostée (rotten fence post des auteurs anglo-saxons). Certaines trabécules présentent des tunnels, des signes de FO (flèches jaunes).

Fig. 10. Distal adolescent fibula AT886 + AT1252. Note the coarsening of metaphyseal trabecular bone evidence of distal fibular subperiosteal resorption and the collapse causing cupping due to resorption of the medial line evidence of hyperparathyroidism (HPT) and renal rickets. Metaphyseal cupping and frayed margins (arrows) can be seen (grade 2 score of rickets). Widening at the growth plate is expected to have existed antemortem. The narrowing seen is an artifact of gluing the two pieces together.
Fibula distale d'adolescent AT886 + AT1252. On observe un grossissement de l'os trabéculaire métaphysaire, témoignant d'une résorption sous-périostée fibulaire distale et un effondrement pariétal entraînant la formation de cavités par résorption de la ligne médiale, témoignant d'une hyperparathyroïdie (HPT) et de rachitisme rénal. Des cavités métaphysaires et des marges effilochées (flèches) sont visibles (grade 2 de la classification des lésions du rachitisme). Il est vraisemblable que l'élargissement de la plaque de croissance existait anté-mortem. Le rétrécissement observé est un artefact résultant du collage des deux pièces.

Fig. 11. Three femoral necks. The inferior parts of three femoral necks (F3, AT-2240 + AT-2118 + AT208, F5) at different stages of growth demonstrating the "rotten fence-post" sign of the primary trabeculae, which is pathognomonic of hyperparathyroidism. The most marked manifestation of this sign is in the middle femur, which is at the height of its growth spurt.
Trois cols fémoraux. Les parties inférieures de ces trois cols fémoraux (F3, AT-2240 + AT-2118 + AT208, F5) à différents stades de croissance présentent une érosion sous-périostée pathognomonique de l'hyperparathyroïdie. La manifestation la plus marquée de ce signe se situe au niveau de la zone métaphysaire du fémur du milieu.

The inner table is normal as reported by Caffey (1978) in rickets. The coarseness of the diploic trabeculae is similar to those described in iliac crest biopsies (Mehls et al., 1975) in the most severe cases of ROD evidence also of hypertrophic rickets (Lewis, 2007; see above 2.2.2) and absence of anemia as there is no widening of the diploic spaces. Rachitic hyperostosis supraorbitally has been reported in dialysis adolescents with ROD (Meredith et al., 1978).

The bone layers are termed rachitic osteoplaques (ROPs; Schultz, 2003). The 4 parallel and regularly spaced rachitic osteoplaques (Fig. 5) signify 4 chronic relapsing episodes which can characterize recidivism of rickets. Rachitic osteoplaques are found in adolescent crania with chronic

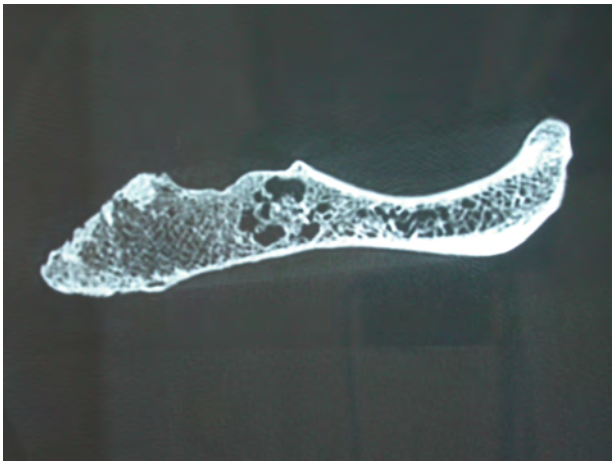

Fig. 12. Brown tumor (BT) in the ilium of Pelvis 1. A multilocular brown tumor in the ilium of Pelvis 1 is shown in the middle. Note the empty spaces of the cysts and the sclerotic rims in the middle of the bone evidence of healing after chronic 2HPT.
Tumeur brune (BT) dans l'ilion du bassin 1. Une tumeur brune multiloculaire est présente au centre de cet ilion. On observe des espaces vides dus aux kystes et une sclérose des bords au milieu de l'os prouvant une guérison après 2HPT chronique.



Fig. 13. Vertebra VC18 (C3) with chondrocalcinosis in annulus firbrosus evidence of CPPD in hyperparathyroidism (HPT) associated with CKD-MBD.
Vertèbre VC18 (C3) avec chondrocalcinose dans l'annulus fibrosus, témoignant de CPPD par hyperparathyroïdie (HPT) associée à CKD-MBD.

rickets (Schultz, 2003) because during pubertal growth spurt the ectocranial table of the frontal bone is displaced anteriorly in front of the frontal sinuses at its highest speed (Moore and Ross, 2017). However, they are not as distinct, regular and compact as here and they are mostly represented by one rachitic osteoplaque which is trabecularized. Since depositional regularity signifies annual periodicity in the edible dormouse (Krystufek et al., 2005), fossil amphibians and reptiles (Peabody, 1961), these 4 layers are annual too and correspond to 4 years of episodic renal rickets. Then the growth spurt of Cranium 9 might have lasted for 4 years.

The gaps between the rachitic osteoplaques were apparently filled by osteoid. Osteoid designates that part of newly deposited bone matrix which is not yet mineralized (Ricqles et al., 1991). The osteoid was preserved in the fossil bones as an empty gap due to its postmortem decomposition. Some hibernators, such as bats (Doty and Nunez, 1985), ground squirrels (Haller and Zimny, 1977) and hamsters (Steinberg et al., 1981) lose bone during and immediately after hibernation. In hibernating bats with 2HPT (Kwiecinski et al., 1987), lines of arrested growth are formed due to osteoid deposition. In chronic, experimental and severe HPT of guinea pigs, the osteoid tissue was laid down soon after the last dose of

Fig. 14. Subperiosteal new bone in Humerus AT-742. Note the subperiosteal new bone (PNB) that is typical for the bones of the SH collection. It is depositional and has a vermicular or round surface porosity. It is evidence of secondary hyperparathyroidism (2HPT).

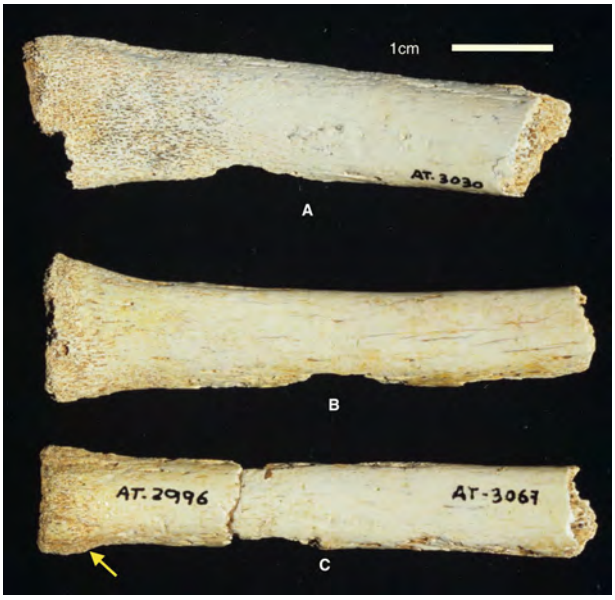

Fig. 15. Beading of the ribs. Beading of the sternal ends (arrow) is shown in ribs AT-3030 (A), AT1241 (B), and more characteristically in AT-2996 + AT-3067 (C) consistent with secondary hyperparathyroidism (2HPT) and rickets diagnosis. Note "mottling" especially to the left of AT-3030.
Perlage des côtes. L'aspect perlé des extrémités sternales (flèche) est observé sur les côtes AT-3030 (A), AT1241 (B), et de manière plus caractéristique sur AT-2996 + AT-3067 (C). Ces aspects sont compatibles avec l'hyperparathyroïdie secondaire (2HPT) et le rachitisme. Notez la présence de marbrures, en particulier dans la partie gauche de l'AT-3030.

PTH was administered i.e., during the healing phase (Jaffe et al., 1931, 1932). These observations and experimental evidences seem to explain what happened to the SH hominins (see 7 below).

The 4 sublayers of the superficial rachitic osteoplaque apparently correspond to 4 interbout arousals from torpor which might correspond to 4 months of hibernation. Since the contrast and the

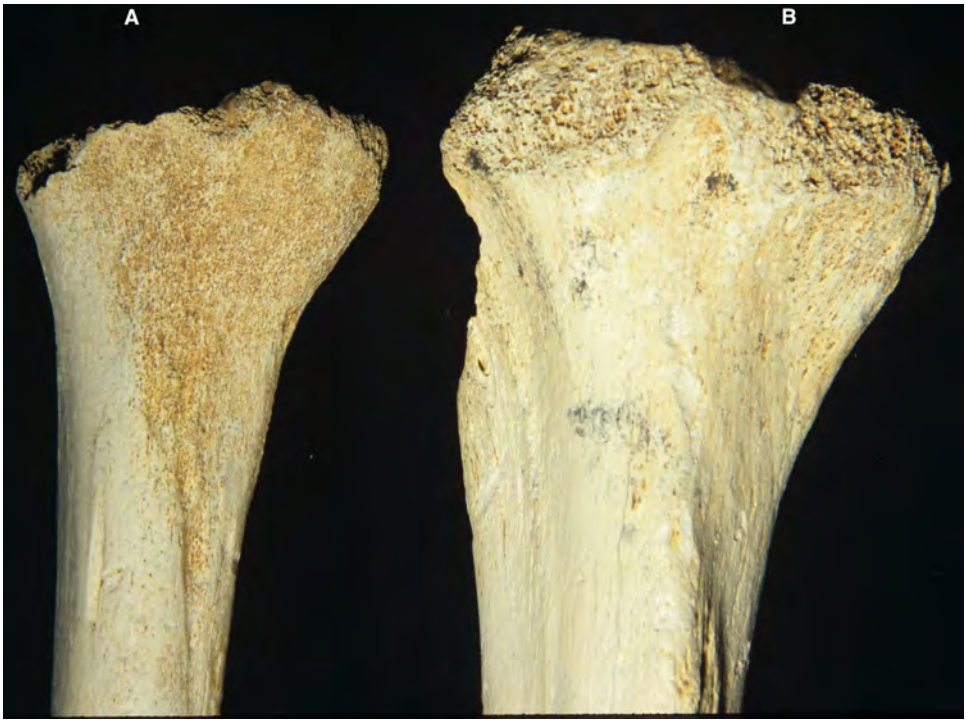

Fig. 16. Adolescent Tibia II (A). Note the porosity (subperiosteal resorption SPR) in the medial cortex evidence of 2HPT and ROD. Adult Tibia III (B). Note that the porosity has largely being healed.
Tibia d'adolescent II (A) : Notez la porosité (résorption sous-périostée SPR) dans le cortex médial, preuve de 2HPT et ROD. Tibia III adulte (B) : la porosité est en grande partie guérie.

Fig. 17. Incisor socket of Cranium 9. Upper right incisor socket of Cranium 9. Note that the lamina dura (LD) has been resorbed and partially lost. It is consistent with the diagnosis of ROD and hibernation in the SH hominins.
Alvéole de l'incisive supérieure droite du crâne 9. La lamina dura (LD) a été résorbée et partiellement perdue. Cet aspect est compatible avec le diagnostic de ROD et d'hibernation chez les hominines de SH.

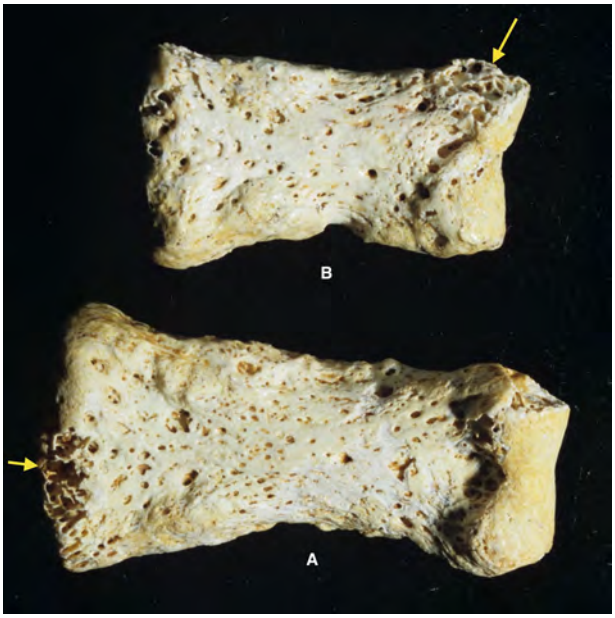

Fig. 18. Hand phalanges. A: AT-2520: palmar view of middle hand phalanx 3 or 4. Subperiosteal lacelike resorption and cortex with many holes are present laterally, medially, and on the palmar surface as evidence of 2HPT. Note loss of normal cortical bone along the lateral margins (Slatopolsky and Delmez, 1998). Note also the juxta-articular subperiosteal resorption (SPR, arrow) at the margin of the proximal interphalangeal joint accounting for the articular manifestation of HPT simulating the appearance of rheumatoid arthritis (Resnick and Niwayama, 1976). B: AT-2521: palmar view of left adult middle hand phalanx 5 with the characteristic subperiosteal lacelike resorption at the sides of the shaft. Note the subperiosteal resorption (SPR, arrow) on the ulnar aspect at the corner of the distal interphalangeal joint (Resnick and Niwayama, 1995a,b) simulating the appearance of rheumatoid arthritis. The most common site of subperiosteal resorption in the joints is the distal interphalangeal joint usually the fourth or fifth (Sundaram et al., 1979). There is also tunneling in the trabeculae.
Phalanges de la main. A : AT-2520 : vue palmaire, deuxième phalange du 3° ou 4° doigt. Une résorption sous-périostée et de nombreux trous corticaux sont présents latéralement, médialement et sur la surface palmaire témoignant de 2HPT. Notez la disparition de l'os cortical normal le long des marges latérales (Slatopolsky et Delmez, 1998). On observe également la résorption sous-périostée juxta-articulaire (SPR, flèche) au bord de l'articulation interphalangienne proximale expliquant l'atteinte articulaire de l'HTP simulant un début de polyarthrite rhumatoïde (Resnick et Niwayama, 1976). B : AT-2521 : vue palmaire de la deuxième phalange du 5° doigt gauche avec la résorption sous-périostée caractéristique sur les côtés de la diaphyse. Une résorption sous-périostée (SPR, flèche) est visible sur la face ulnaire au coin de l'articulation interphalangienne distale (Resnick et Niwayama, 1995a,b) simulant un début de polyarthrite rhumatoïde. Le zone de résorption sous-périostée articulaire la plus courante est l'articulation interphalangienne distale, généralement la quatrième ou la cinquième (Sundaram et al., 1979). Il y a aussi des tunnels dans l'os trabéculaire.

distinctness between depositional zones is most pronounced in hibernators (Morris, 1972; Klevezal, 1996) where there is an almost total cessation of activity for part of the year, it follows that the sharp contrast between the ROPs and the gaps in Cranium 9 are evidence of hibernation in this individual too. So, we term these gaps as Hibernational Zones of Arrested Growth (HZAGs). After all, interrupted bone deposition is considered as evidence of hibernation (Chinsamy et al., 1998) and the distinctness of lines of arrested growth may be related to whether the animals hibernate or not (Cool et al., 1994). Therefore, the presence of these gaps (i.e., HZAGs), the annuality of rachitic osteoplaques and their distinctness, and the sublayers of the last ROP are conclusive evidences for hibernation in the SH population in dark cavernous hibernacula.

It is interesting that during the recovery phase in the experimental HPT (Jaffe et al., 1931, 1932), BT's, OF and extensive enlargement of the Haversian canals took place. These lesions are also characteristic of the present collection.

Radius. Layered zones such as those in Cranium 9 are also found in long bones especially those in growth spurt. Since they are often found in many skeletal species here and especially those of adolescents, this also indicates that they are annual (Peabody, 1961). Fig. 6 shows radius AT-4216 and

its natural cross section at the level of radial tuberosity. It is in puberty as the flake epiphysis for tuberosity is discernible subperiosteally. Note the thick layers of bone deposited every year and the fine trabeculae between them. One can see 4 of those layers; this ties with the fact that the flake epiphysis of the radial tuberosity appears and fuses in puberty that lasts 4 years in modern humans. This histology shows that there is puberty in SH hominins that takes more or less the same time as that in modern humans but it is intermittent (i.e., seasonal) because of hibernation.

4.3. Craniotabes

There is also flattening of the posterior of Cranium 9 at the parietals with a slight depression toward their middle (Fig. 7) giving an angular appearance to the skull (Fig. 3). This is known as craniotabes or *caput quadratum* that is the clinical hallmark of rickets (Aufderheide and Rodriguez-Martin, 1998). It may lead to posterior flattening of the parietal bones (Caffey, 1978) and the formation of a large, square (Aufderheide and Rodriguez-Martin, 1998; Brickley and Ives, 2008) or triangular (Jaffe, 1972) shaped head. Craniotabes may develop a parietal eminence in the sides of the parietal bones following the incessant overproduction of osteoid in these bones (Pezeshk and Carrino, 2009) during a time of rapid skull growth (Jaffe, 1972), as during adolescence. This diagnosis is confirmed by the tunneling (OF) of the diploic trabeculae observed for instance in the right craniotabe close to the parietal eminence (Fig. 8). Indeed, tunneling of the diploic trabeculae occurs in HPT (Resnick and Niwayama, 1995a,b; Jaffe, 1972) close to the parietal eminence as it is the area mostly affected by rapid growth. Therefore the craniotabes of Cranium 9 and their histology are evidence of Vitamin D induced 2HPT.

The adolescent Cranium 3 appears to have periosteal new bone around the parietal eminences Arsuaga et al., 1997, their Fig. 1) indicating healed craniotabes from rickets.

4.4. Craniosynostosis

The craniosynostosis of adolescent Cranium 14 (Gracia et al., 2009, 2010) is consistent with the identification of rickets (Steinbach et al., 1959; Reilly et al., 1964; Duggan et al., 1970; Wang et al., 2007), HPT (Aviv et al., 2002) and ROD (Reilly et al., 1964; Boia et al., 2007) in the SH collection.

There is a paradox in rachitic craniosynostosis concerning on one hand the delay of ossification and hypomineralization caused by rickets and on the other the premature sutural fusion (Cohen, 1988). This is because the above diseases occur in cycles and have a healing phase during which the sutural fusion takes place. This is the reason why some rachitic children develop early craniosynostosis before the age of 9 years when the active phase of the disease stops and healing progressed (Reilly et al., 1964; Duggan et al., 1970). This is consistent with the biological age (at least 10 years) attributed to Cranium 14 (Gracia et al., 2010).

From Table 2 we can deduce that 3 out of 5 adolescent crania bear evidence of rickets. Since about half of the adolescent crania have rickets, this may reflect a different sexual response to hibernation. For instance, one sex may accumulate more fat than the other or have longer hibernation times.

4.5. "Rotten fence post" sign

In the unfused distal femora (such as in the femur AT-2240 + AT-2118 + AT208), the metaphyseal trabeculae are exposed (Fig. 9). Many of them show tunneling, evidence of OF. This is known as the 'rotten fence post' sign. It forms when the resorptive process at the outer metaphysis continues after longitudinal growth has ceased and creates the sign of the 'rotten fence post' in radius, ulna and femur underneath the overriding cartilage plate (Krempien et al., 1974) due to OF in 2HPT (Parfitt, 1972). The 'rotten fence post' sign is diagnostic for renal rickets' (Teall, 1928) and has an alternating strut/slit histology (Ortner and Mays, 1998) that resembles the bristles in a brush (Caffey, 1978). These "woolly" lesions represent metaphyseal subperiosteal resorption. The 'rotten fence post' sign is also shown in Fig. 1 of Mays et al. (2007) in 2HPT. Thus, the lesion with the trabeculae exposed in Fig. 8 is identical to the 'rotten fence post' sign evidence of OF, renal rickets and 2HPT in the SH hominins.

The distal fibula AT886 + AT1252 is from an adolescent as the epiphysis is not fused (Fig. 10). Note the coarsening of metaphyseal trabecular bone evidence of 'rotten fence post' and distal fibular

subperiosteal resorption as described (Murphey et al., 1993) in renal rickets, 2HPT and ROD. Also metaphyseal cupping and frayed margins can be seen (Fig. 10).

A special case of "rotten fence post" sign appears in the medial margins of the femoral necks. Fig. 11 shows the inferior parts of three femoral necks (F3, AT-2240 + AT-2118 + AT208, F5) at different stages of growth. The trabecular columns and osteoid voids run parallel to the bone surface in the femoral neck. The development of this sign depends on the intensity of growth. Thus, the biggest femur without epiphyseal fusion has the most marked manifestation of this sign (middle of Fig. 11). The signs of this feature in the other femora are not so developed and in the fully adult it has completely disappeared. There is also a flattening of bone beneath the femoral head (Fig. 11). This lesion is a particular type of 'rotten fence post' sign and subperiosteal resorption in ROD in concave areas ('cutback zones'), such as the medial margins of the femoral necks (Resnick, 1995; Swischuk and Hayden, 1979) especially in adolescents (Murphey et al., 1993; Swischuk and Hayden, 1979; Goldman et al., 1978). It results in the diminution in the number of trabeculae, and a compensatory thickening of primary stress trabeculae (Weller et al., 1968) as here. The 'rotten fence-post' sign along the shaft of the (inferior) femoral neck (Lewis, 2007; Kirkwood et al., 1972) is typical and pathognomonic of hyperparathyroidism (HPT) in femora (Kirkwood et al., 1972).

Since this sign occurs in adolescents during growth spurt (Sundaram, 1989; Resnick, 1978) and because ROD is directly related to the growth rate (Marini et al., 1992; Kirkwood et al., 1972), it is deduced that the SH hominins too underwent a growth spurt as shown by the intensity of its manifestation in the necks of the SH femora. The existence of puberty is confirmed by 'the strong projection of the external lip of the femoral trochlea' in the late adolescent distal femoral epiphyses of SH which is diagnostic of adolescence in hominins (Tardieu, 1998). The above finds are the first conclusive evidence of adolescent growth spurt not only in the SH hominins but in paleoanthropology generally.

4.6. Brown Tumour

The CT scan of the ilium of the adult Pelvis 1 displays an aggregation of multiple cysts without internal structure divided by septa and surrounded by a narrow band of marginal sclerosis (Fig. 12). These are termed Brown Tumours (BTs) and are conspicuous only in this pelvis.

Another particular type of OF is the brown tumour that is formed at an end stage of hyperparathyroidism (HPT; Schiller, 1994) and CKD (Bereket et al., 2000). Brown tumours are generally multiple cystlike lytic lesions (Knaggs, 1923) that represent reparative granulomas (Jaffe, 1972) that may be present anywhere in the skeleton (Steinbach et al., 1961; Shapiro, 1972). An excessive secretion of PTH leads to OF and BTs in order to partially restore serum calcium levels to normal (Netter, 1987; Marini, 1992). This excessive bone resorption leads to large well-demarcated spaces filled partially with osteoclasts (Lee et al., 1996). Brown tumours are especially prominent in the most severe manifestations of ROD during vitamin D treatment (Lewis, 2007). After therapy, thicker sclerotic rims with no internal structure are formed (Adler, 2000; Lee et al., 1996).

The morphology of the cysts in the Pelvis 1 fits exactly the above description of brown tumours and shows that a lytic process after a severe long-standing secretion of PTH has taken place followed by healing as evidenced by the sclerotic rims. This is consistent with the resorption in the symphysis pubis of the Pelvis 1 as such resorptions in the articular cortices of symphysis pubis are especially subject to shearing forces in chronic renal insufficiency (i.e., CKD) and hyperparathyroidism (HPT; Resnick and Niwayama, 1995a,b; Shapiro, 1972; Teng and Nathan, 1960; Ritz et al., 1973). It is also consistent with the experimental HPT (Jaffe et al., 1931, 1932). Therefore, the brown tumours here are pathognomonic of severe long-standing rickets, 2HPT, and ROD i.e., CKD that have been healed in this specimen. The presence of erosive changes elsewhere in this collection supports the diagnosis of brown tumour too (Tigges et al., 1995).

4.7. CPPD

The adolescent vertebra VC18 (C3, Fig. 13; Gomez Olivencia, 2009; Gomez Olivencia et al., 2007) shows an elliptical cartilage calcification of the annulus fibrosus. This is a rare example of an ossified soft tissue in paleoanthropology that has been preserved and fossilized. Such a complete calcification of the C2/C3 intervertebral disk is presented in a radiograph provided by Freyschmidt et al. (2003) in

modern humans (their Fig. 5.211). Similarly, the scapula AT-2563 + AT-2471 has a peripheral ridge in the glenoid cavity that is apparently the result of mineralization of the fibrocartilagenous glenoid lambrum. CPPD (Calcium pyrophosphate dihydrate crystal deposition disease/chondrocalcinosis) is most common in annulus fibrosus of the intervertebral disc and glenoid labra among many sites (Resnick and Niwayama, 1995a,b; Dodds and Steinbach, 1968; Grech et al., 1985). Enthesopathic calcification and ossification may develop in the annulus fibrosus and capsules of apophyseal and appendicular joints (Pitt, 1988). There is close association of CPPD with HPT or chronic renal failure (Resnick and Niwayama, 1995a,b; Dodds and Steinbach, 1968; Markel and Hart, 1982). Therefore, the lesion in vertebra VC18 (Fig. 13) and the aforementioned scapula is consistent with CPPD in HPT associated with the CKD-MBD identification in these SH hominins.

4.8. Subperiosteal new bone (PNB)

A striking lesion in much of the SH hominin collection is the development of thin patches of porous material on cortical bone surfaces (Fig. 14) with vermicular or round pores and oblique orientation of them.

Similar lesions in cortical bone with inclined porosity have been reported (Resnick and Niwayama, 1995a,b) in human archaeological remains with 2HPT. They are called subperiosteal new bone or periosteal neostosis (Resnick, 1995). The common occurrence of subperiosteal new bone in the SH bone collection implies that we are dealing with only one population of hominins that was affected by the same disease(s) which probably had the same environmental etiology to affect the whole population. This is consistent with the view that the bones belong to the same biological population because of the relative morphological homogeneity of the SH collection (Bermudez de Castro et al., 2003). Subperiosteal new bone is an indicator of intense secondary hyperparathyroidism (2HPT), osteitis fibrosa (OF) and advanced hypertrophic rickets or osteomalacia in severe renal osteodystrophy (ROD) during healing (Caffey, 1978; Mays et al., 2007; Heath and Martin, 1970; Meema et al., 1974, 1986; Adams, 1997; Rosenthall and Rush, 1986; Tamarozzi et al., 1984). Subperiosteal new bone may remain evident for years after healing (Caffey, 1978) by vitamin D therapy (Heath and Martin, 1970; Robinson et al., 1982). That is why subperiosteal new bone is common in the SH collection.

4.9. Beading in ribs and tibial subperiosteal resorption

Ribs. Beading of the sternal ends is shown in ribs AT3030, AT1241, and AT-2996 + AT-3067 (Fig. 15). 'Mottling' (which corresponds to the "rotten fence post" sign) is more conspicuous in AT-3030 (Fig. 15). In rickets or osteomalacia and 2HPT, there is beading (i.e., rachitic rosary) at the sternal ends and "mottling" (Pezeshk and Carrino, 2009; Tardieu, 1998). Therefore, the beading in the ribs of Fig. 15 is evidence of 2HPT and renal rickets.

Tibia. A scalloping-like porosity can be seen in the upper medial cortex of adolescent Tibia II (epiphyses unfused, Fig. 16). The posterior and medial surfaces are also affected but the lateral one is the least affected. The porosity reaches the height of the nutrient foramen at its lower end. The lesion is superficial. For comparison, the lesion in the adult Tibia III (Fig. 16) has been largely healed. Only sparse porosity remains. This description fits well that of subperiosteal resorption (SPR) in 2HPT as such subperiosteal resorption has been found in the tibiae of dialysis patients with HPT (Potter et al., 1974). So, the subperiosteal resorption in the upper medial cortex of the Tibia II is evidence of 2HPT (Resnick and Niwayama, 1995a,b; Steinbach and Noetzli, 1964). The lesion is usually scalloping in humans (Gomez Olivencia, 2009; Murphey et al., 1993), as it is in experimental rats with ROD (Dreizen et al., 1967) and always shallow. Many of the lesions in the SH collection such as scalloping subperiosteal resorption and rachitic hyperostosis are those of dialysis patients with ROD too. Therefore, we are dealing here with the acquired type of ROD with evidence of healing.

4.10. Lamina Dura (LD)

In the socket of the upper right incisor of Cranium 9, the partial loss of LD expands away from the mouth of the tooth socket towards the root region (Fig. 17). In the older or younger individuals the LD is more preserved.

The lamina dura (known also as lamina cribrosa or cribriform plate) is compact bone that lies adjacent to the periodontal ligament, in the tooth socket. It is pierced by many small openings for blood vessels, lymphatics and nerve fibers (Dreizen et al., 1967; Berry, 1973). Resorption of LD leads to the loss of lamina dura (Dreizen et al., 1967) which is a sign of OF; this resorption is another instance of SPR (Walsh and Karmiol, 1969) since the periodontal membrane is a specialized periosteum (Walsh and Karmiol, 1969) and alveolar bone is more sensitive and reactive to outside influences than basal bone (Duteroo, 1991). Depending on the severity of the disease, LD may be partially or completely absent (Steinbach and Noetzli, 1964) and the nutrient canals appear wider than normal and are particularly evident in the incisor-canine area (Walsh and Karmiol, 1969; Kaye et al., 1960) as here. In vitamin D deficiency rickets and HPT, loss of the LD around the teeth is frequently seen (Pettifor and Daniels, 1997). OF, chronic azotemic renal failure, and chronic renal insufficiency (i.e., CKD) with 2HPT are all associated with disappearance of the LD (Shapiro, 1972; Kaye et al., 1960; Soderholm et al., 1974; Renton, 1998). In up to 47% of cases of ROD there is loss of LD (Maxwell et al., 1977; Krook and Barrett, 1962). Similarly, there is loss of lamina dura in both osteomalacic and 2HPT primates (Dreizen et al., 1967; Krook and Barrett, 1962). Not surprisingly, loss of LD in small hibernators is effected during hibernation (Aufderheide and Rodriguez-Martin, 1998; Haller and Zimny, 1977).

4.11. Phalangeal resorption

Some phalanges, such as AT-2520 and AT-2521 (Fig. 18), present a ragged porotic shaft with 'bumpy' irregularities as a result of an extensive subperiosteal "lacelike" resorption laterally, medially (cf. Shapiro, 1972; Katz et al., 1969) and on the palmar surface (cf. Katz et al., 1969) that has affected extensively the cortical bone.

This is called phalangeal resorption and it is pathognomonic of severe chronic 2HPT and CKD (Resnick and Niwayama, 1995a,b; Robinson et al., 1982). Phalangeal resorption is the earliest, the most common and the most sensitive sign of 2HPT (Slatopolsky and Delmez, 1998; Adams, 1997; Sundaram, 1989). It results from hypocalcemia induced by vitamin D deficiency (Adams, 1997). In advanced cases of 2HPT most of the cortical surface may suffer from phalangeal resorption (Shapiro, 1972) as in the present case. The round holes in the cortical bone (Fig. 18) may be due to a cumulative resorptive effect of PTH over the years as it is the case in dialysis osteoarthropathy in 2HPT (Naidich et al., 1987). In AT-2520 and AT-2521 there are also periarticular resorptions (Fig. 18). While they are not pathognomonic, occur frequently in 2HPT (Hamilton and Knickerbocker, 1982) and their pattern is unlike that of other erosive arthropathies (Hamilton and Knickerbocker, 1982; Johnson et al., 1967). In some other phalanges with diaphyseal resorption [e.g. in the left adult middle phalanx 5 (AT-1304) and in the subadult middle hand phalanx 3 or 4 (AT-3154)], subperiosteal new bone has also been formed on the dorsal surface (Rosenthall and Rush, 1986; Tamarozzi et al., 1984). Indeed, subperiosteal new bone is always accompanied by SPR in finger bones (Heath and Martin, 1970; Meema et al., 1974, 1986; Adams, 1997; Rosenthall and Rush, 1986). In AT-98 there is resorption of the terminal tufts, not unexpectedly, since in ROD there is a marked acro-osteolysis of distal phalanges of foot (Lewis, 2007). OF tunneling is also present in some of the phalangeal trabeculae.

5. Differential diagnosis

5.1. Evidence for CKD-MBD

Most of the lesions we mentioned in SH are pathognomonic. For instance, Osteitis Fibrosa (OF) in the trabeculae is pathognomonic of 2HPT, ROD and CKD-MBD. Rachitic hyperostosis is pathognomonic of rickets. The supraorbital area (Figs. 4 and 5) bears 4 osteoplaques evidence of episodic disease. These are rachitic osteoplaques (ROPs) but their detailed histology is different from that presented by Schultz (2003) as in essence he refers to one spongy osteophyte whereas here the osteoplaques (ROPs) are compact and have gaps (HZAGs) between them. His "osteoplaque" refers to a subadult skull (Schultz, 2003, his Figs. 6–13) and it is only by name an osteoplaque as in essence it is an osteophyte that is spongy, discontinuous, not well defined and the entire thickness of the bone has the

appearance of diploe (Schultz, 2003). This is not the case here where the osteoplaques are compact (apart from the superficial one which did not have time to remodel).

Craniotabes are pathognomonic of rickets. The brown tumours are pathognomonic of severe long-standing rickets, 2HPT, and ROD i.e., CKD and are evidence of healing. The "rotten fence post sign" is evidence of OF, renal rickets and 2HPT in ROD i.e., CKD. The rachitic rosary is pathognomonic of rickets.

Phalangeal resorption is pathognomonic of severe chronic 2HPT and CKD (Resnick and Niwayama, 1995a,b; Robinson et al., 1982). The pattern of the SPR at the margins of the phalangeal joints is unlike that of other erosive arthropathies such as rheumatoid arthritis Ortner and Utermohle, 1981). In rheumatoid arthritis the diaphyseal bone is commonly free of subperiosteal resorption (Rothschild and Martin, 1993). Erosive osteoarthritis, distinguished by associated osteophytes and subchondral sclerosis, predominantly involves first carpometacarpal and first metatarsophalangeal joints, but rarely involves intercarpal or metacarpophalangeal joints. Phalangeal resorption is not found in hyperthyroidism (Meema and Oreopoulos, 1983).

PNB is evidence of healing in intense 2HPT, OF and advanced hypertrophic rickets in severe ROD. Conditions associated with subperiosteal new bone include scurvy, Caffey's disease, infections and malignancies (Kwon et al., 2002) but their detailed histology is different. For instance, in vitamin C deficiency the trabeculae of the pores are perpendicular to the bone surface (Rothschild and Martin, 1993) whereas here a large part of the pores' trabeculae are inclined (Fig. 14). In rheumatoid arthritis, PNB is notable in its absence (Rothschild and Martin, 1993; Klepinger, 1979) and the diaphyseal bone is commonly unaffected (Rothschild and Martin, 1993) whereas here the opposite is the case.

LD is not an infallible diagnostic sign of HPT: loss of lamina dura may also occur in osteomalacia, Paget's disease, fibrous dysplasia, sprue, neurofibromatosis, Addison's and Cushing's syndrome, myelomatosis, diffuse metastasization and leukaemias. Especially in osteomalacia, loss of lamina dura occurs because teeth are considered as Vitamin D_3 controlled mineralized tissues (Bailleul-Forestier et al., 1994). The diagnosis of HPT is accurate only when all areas are considered (Berry, 1973) for evidence of subperiosteal resorption and OF (Walsh and Karmiol, 1969; Fletcher et al., 1977) and this is the case here. Therefore, the loss of LD in Cranium 9 is consistent with the hypothesis of ROD (2HPT, osteomalacia and OF) associated with CKD and hibernation in the SH hominins.

In conclusion, the constellation of gross and histological attributes described above is distinct to ROD associated with CKD-MBD which is the oldest in the skeletal record: there is conclusive pathognomonic evidence for OF, chronic 2HPT and hypertrophic renal rickets in ROD evidenced at least by the trabecular tunneling, the 'rotten fence post' sign, the rachitic hyperostosis, the craniotabes, the brown tumours, the phalangeal resorption and the extra-skeletal calcification (CPPD). Mottling, subperiosteal resorption and beading of the sternal ends of ribs are pathognomonic of renal rickets and 2HPT. The presence of subperiosteal new bone shows the presence of 2HPT in severe ROD during healing. The CKD-MBD is confirmed by the presence of ROD lesions and the extra skeletal calcification (CPPD).

5.2. Evidence for puberty

As it has been shown, puberty is evidenced by the different intensity of "rotten fence post sign", the subperiosteal resorption, 'the strong projection of the external lip of the femoral trochlea', and the rachitic hyperostosis in the supraorbital area in the adolescent cranium 9.

Because rickets and 2HPT are diseases of growth, then in the SH juveniles, the flake epiphysis for tuberosity in the radius (Fig. 6) and the severe expressions of rickets and 2HPT such as the presence of tunneling trabeculae (OF), the resorption of LD, the 'rotten fence post' sign, the SPR and their degree of manifestation in the SH adolescents, 'the strong projection of the external lip of the femoral trochlea', the evidences of healing and the presence of regularly spaced rachitic osteoplaques (ROPs) and gaps (HZAGs), all show that the SH individuals had an intermittent (seasonal) pubertal growth spurt. This is because the bone manifestations of rickets are most striking at the time of greatest growth speed at puberty (Soliman et al., 1996) as its high growth rates result in high metabolic and nutritional demands (Leigh, 1996). This is even more so in the case of adolescents with renal rickets, HPT, and ROD (Follis, 1950; Crutchlow et al., 1971) caused by inadequate renal production of vitamin D (Chan et al.,

1981), which results in growth failure. Therefore, it may be possible that some of the SH adolescent children developed a severe vitamin D deficiency which caused marked 2HPT and bone morphology identical to patients with ROD associated with CKD-MBD. This is confirmed by the fact that severe cold decreases the secretion of growth hormone (Donahue et al., 2006; Pääkkönen and Leppäluoto, 2002).

5.3. The evidence for hibernation

Rickets and ROD has been reported in troglophile hibernators such as cave bears and bats (Kwiecinski et al., 1987; Breuer, 1931; Nelson et al., 1983). Therefore, the SH hominins present the same diseases as those of animal hibernators. These diseases are consistent with the hypothesis of hibernation in the SH hominins. Especially, the gaps (i.e., the Hibernational Zones of Arrested Growth, HZAGs) between the ROPs are diagnostic of hibernation. Rickets does not present such manifestations and has no gaps (HZAGs). The frontal bone is not compact in rickets but spongy (see above 5.1). The 4 sublayers in the superficial rachitic osteoplaque (ROP) of cranium 9 are diagnostic of interbout arousals from hibernation. This can be explained metabolically as follows.

Increased breakdown of adenosine triphosphate (ATP), is thought to be one reason as to why crystals in CPPD may develop and mineralize the articular cartilage (Ryan et al., 1992). Brown adipose tissue (BAT) is found only in mammals and differs from white adipose tissue (WAT) in that it generates heat at the expense of ATP (Rosen and Spiegelman, 2006). Thus, lipolysis of BAT resulting in increased production of ATP and its breakdown (see also 2 Introduction) may have been responsible for the excessive deposition of crystals and formation of CPPD that resulted in the mineralization of annulus fibrosus of vertebra VC18 (Fig. 13), as BAT generates heat during arousals from hibernation. Therefore, in the present case, CPPD is evidence of lipolysis of BAT during interbout arousals from hibernation. This is confirmed by the 4 sublayers of the interbout arousals in the last rachitic osteoplaque (ROP) of Cranium 9 (Fig. 5) which are diagnostic of hibernation.

We have shown that the lesions described here in the SH hominins are those suffered by cave hibernators in a state of poorly tolerated hibernation. Some of these, such as the HZAGs, are diagnostic of hibernation. Hibernation is characterized by bouts of torpor (Carey et al., 2003) and interbout arousals (Pengelley and Fisher, 1961; Geiser, 1995). We have provided evidence for interbout arousals in the SH hominins in the form of sublayers of the superficial rachitic osteoplaque (see 4.2) and CPPD (see 4.7). One month for one hibernation bout, as suggested here for the SH hominins, is not as improbable as it may seem: primates, like *Microcebus griseorufus*, can hibernate without arousals for months (Blanco et al., 2018; Kobbe et al., 2011).

Then, these hominins might well have stayed continuously for a long period of at least some 4 months (corresponding to the 4 sublayers of the last rachitic osteoplaque, ROP) inside a cave to develop such a severe chronic rickets and 2HPT (i.e., CKD-MBD) unique for human bones found in caves world wide. A strategy of hibernation would have been the only solution for them to survive being for months in a cave due to the frigid conditions. Indeed, the cave bear *Ursus deningeri* found in SH in the same horizon with the humans was hibernating too (Garcia and Arsuaga, 2010). This close stratigraphic relation and behavior of the SH hibernating bears with the SH humans, makes it more sensical to suggest that the SH hominins developed a similar adaptation to hibernation during glaciation in order to survive the frigid conditions and food scarcity as did the cave bears. Indeed, a juvenile skull of a hibernating fossil bear of *U. deningeri* from SH does show evidence of rickets (PNB) on its cranium. Besides, there is no skeletal evidence for acquired rickets or CKD-MBD in modern humans from any cave in the world.

The adolescent mortality distribution in the SH hominins in which there is 'an abnormally high percentage of adolescents' (Bermudez de Castro et al., 2004) is characteristic of hibernation-related mortality in typical cave bear sites (Debeljak, 2007) such as in the bears of Mokrica cave of Slovenia (see 2.1) : in SH 85.7% are teenagers or young adults (Bermude de Castro et al., 2020), an abnormal adolescent mortality that reminds famine (Krovitz et al., 2003). The intermitted (seasonal) nature of growth spurt was caused apparently by their inability to build up a sufficient store of fat (see e.g., Breuer, 1931) for the winter hibernations. The dental and endocranial volume evidence is consistent with this conclusion (Bermudez de Castro et al., 2003). Apparently, some of the SH adolescents did not

have enough stores of fat to support both their fast growth and hibernational demands as shown by the diseases they suffered in contrast to the adult individuals. The hypothesis of hibernation in SH is consistent with the catastrophic profile of mortality suggested by Bermudez de Castro et al., (2020).

Another human species from Atapuerca *Homo antecessor* (MIS 21; Bermudez-de-Castro et al., 2017) from the nearby caves of Sima del Elefante does not bear any evidence of the pathologies associated with hibernation such as those in SH even though adolescent frontal bone(s) of it were found. This is because MIS 21 corresponds to a warm and humid climate (Kitaba et al., 2011). These pieces of evidence show that the lesions reported here have nothing to do with the latitude of Atapuerca and the annual UV radiation. Since the latitude is not the cause, the climate might be the cause for their hibernation. Indeed, the time the SH hominins lived — circa 448 Ka ago (MIS 12) — coincides with the glacial period that was the most severe and long of the last 1 million years (Demuro et al., 2019). If today's climate in Atapuerca features chilly and windy winters, which always includes snow and temperatures below freezing often as low as −10 °C, one can only imagine how more severe the cold would have been like in the glacial times of the SH hominins. Thus, the hibernation hypothesis is consistent with the climate of the time.

In conclusion, the poorly tolerated hibernation has caused chronic vitamin D deficiency, renal rickets and 2HPT in ROD associated with CKD-MBD and has induced growth arrest and formation of rachitic osteoplaques and gaps (HZAGs) in the adolescents of SH. The above bone evidence expressed annually shows that the SH hominins used hibernation as a survival strategy to face winter famine and cold. Such compact rachitic osteoplaques (ROPs) as those reported here, along with their gaps (HZAGs) and their distinctness are unique features in the human or animal skeletal record and are unequivocal evidence of hibernation.

6. Alternative etiological hypotheses of the potential causes of CKD-MBD other than hibernation and associated criticism

6.1. The climate in the Iberian peninsula would not be severe enough to encourage hibernation in a hominin such as that of SH

The SH hominins lived during the Marine Isotope Stage (MIS) 12 and have an age of 448 ± 15ka (Demuro et al., 2019). This severe glacial period was the most extreme glaciation during the last 1 million years characterized by aridification of Iberia, low vegetation cover and rapid snowmelt (Demuro et al., 2019) which all imply food scarcity of the SH hominins. These conditions would have been even more pronounced in the high elevation of the SH locality of at least 1000 masl. Thus, the above hypothesis is false.

On physiological grounds, cold stimulates the secretion of cortisol from the adrenal gland that increases heat production by activating the mitochondria of BAT and WAT (Pääkkönen and Leppäluoto, 2002) to induce lipolysis. BAT is a tissue used by hibernators during arousals from hibernation bouts (Nedergaard and Cannon, 1990). Cortisol increases bone resorption (Raisz, 1984) and decreases bone formation (Donahue et al., 2003) by inhibiting calcium absorption in the intestine thus leading to 2HPT (Raisz, 1984). Cortisol increases in hibernating animals, such as bears (Donahue et al., 2006) and bats (Gustafson and Belt, 1981), a condition that in some males of the hibernating mouse lemur *Microcebus murinus* leads to hypercortisolism and death from chronic glomerulonephritis (Perret and Predine, 1984). Cortisol also increases collagen synthesis i.e., osteoid formation (Rosen and Luben, 1983). Severe cold decreases the secretion of growth hormone too (Pääkkönen and Leppäluoto, 2002). Because cortisol inhibits Ca absorption and increases bone resorption, it leads to vitamin D deficiency and 2HPT.

The above physiologies due to cold may explain the presence of HZAGs and arrested growth in the SH hominins. Thus, the HZAGs and their sublayers are evidence of cold, cortisol action, lipolysis, vitamin D deficiency, hyposecretion of growth hormone, 2HPT and ultimately hibernation in the SH hominins (see also 6.3). Thus, the SH hominins may well have developed such adaptations to cold and high altitude to survive the glacial conditions (see also 2.1). Indeed, the SH hominins are genetically closely related to Denisovans (Meyer et al., 2014) who were adapted to cold and high altitude (Huerta-

Sánchez, 2014; Racimo et al., 2017) some genes of which have been associated with the activation of the adrenal gland and BAT in humans (Racimo et al., 2017).

Thus, the above hypothesis is also false on physiological grounds too.

6.2. The skeletal pathologies in SH are only due to starving

Starvation alone outside caves (i.e., without lack of sunlight) is often leading to vitamin deficiencies such as beriberi, pellagra and scurvy but cannot lead to vitamin D deficiency. Thus, the above hypothesis is false.

6.3. The skeletal pathologies in SH are only due to lack of sunlight because of cave dwelling which causes severe Vitamin D deficiency

Every day cave dwelling has never produced any vitamin D deficiency: all the recent anatomically modern human skeletal material found so far in caves worldwide bear no evidence of acquired rickets (see also 5.3). This is because they were not living constantly in their caves but they were venturing in and out of the cave on a daily basis for feeding and therefore they were not hibernating. The assumption that modern humans are reasonable analogs for extinct human species is not always correct (Aiello, 2006). Thus, the above hypothesis is false.

On physiological grounds, constant darkness alone can activate genes that can trigger lipolysis to generate endogenous energy from fat by inducing increases in serum 5′-AMP and c-AMP (Lee, 2007) which stop food intake, activate procolipase expression, and induce hypothermia, all features of hibernation (see also 1. Introduction and 1.2). The primary role of procolipase is in breaking down dietary fat into fatty acids (Lee, 2008). For instance, in mice, 'there is a mechanism by which constant darkness regulates the gene expression of fat catabolic enzymes' to induce lipolysis (Zhang, 2006). Lipolysis takes place *long before* vitamin D deficiency has the time to develop because lipolysis effected by constant darkness provides vitamin D already stored in white adipose tissue. More importantly, lipolysis is not the only effect of constant darkness: osteoid deposition markedly increases in vitamin D deficient rats kept in constant darkness for one month (Rosenstreich et al., 1971). Thus, constant darkness causes increases in cortisol levels (Donahue et al., 2003), which induce lipolysis and osteoid formation that lead eventually to vitamin D deficiency and 2HPT during hibernation.

This is exactly what may have happened in the SH hominins: when all the fat was used due to constant darkness and the calcium absorption in the intestine was inhibited, most of the action of PTH consisted in mobilizing more mineral from bones causing bone deformities as calcium could no more be deposited in the new osteoid formed (Li et al., 1997) thus forming seasonal gaps of osteoid (i.e., HZAGs).

Therefore, apart from cold, constant darkness too can trigger lipolysis inducing a state of hibernation in a dark den before the development of vitamin D deficiency takes place. Rickets develops later when the fat and vitamin D stores are depleted. Osteoid (collagen) and HZAGs are not only produced by constant darkness but by hypercortisolism due to cold as well (see 6.1). Thus, it is possible that the SH individuals developed vitamin D deficiency only due to prolonged constant darkness and to cold that were the trigger for cortisol secretion, lipolysis, hypocalcemia, vitamin D deficiency, 2HPT, ROD and annual formation of ROPs and HZAGs because they lived constantly in the cave hibernating during winter. Vitamin D deficiency and rickets alone do not produce annual HZAGs and ROPs.

Thus, the above hypothesis is false on physiological grounds too.

6.4. The Neanderthals did not hibernate. Why the SH hominins (H. heidelbergensis) should hibernate?

This is because the Neanderthal morphology was better adapted to cold and dry environments than that of *H. heidelbergensis* (Wroe et al., 2018) as the Neanderthals had a high base metabolic rate (BMR; Aiello, 2006). To satisfy their energy demands, Neanderthals specialized in hunting mammoths, bos/bison, red deer and horse (Power, 2019), which were high in, fat rich in vitamin D and provided them with food year round. This is confirmed by the fact that the type specimen of Neanderthals (found in

the Feldhofer cave) suffered neither from rickets nor from CKD-MBD (Schultz, 2006). To the contrary, hibernators are characterized by hypometabolism during hibernation and reduced BMR (Stenvinkel et al., 2013). Thus, the above argument is unfounded.

6.5. None of the indigenous arctic populations such as the Inuit and the Sami today hibernate despite they live in very cold environments

This is because fat rich in vitamin D is available in these populations year round (as it was in the case of Neanderthals) so that they do/did not need to hibernate. For instance, the Inuit diet is high in fatty fish and marine mammals that are rich in polyunsaturated fatty acids (PUFAs) for which they have genetic and physiological adaptations (Fumagalli et al., 2015). Similarly, traditional Sami diet is rich in fatty fish and reindeer fat (Nilsson et al., 2012; see 2.2). The availability of such food is also true for the archaeological arctic populations who were able to exploit many sources of fat-rich food year round (Aigner, 1985). As a result of their higher energetic demands during the winter, the indigenous arctic populations (like the Neanderthals) have an elevated base metabolic rate (BMR; Leonard et al., 2002). In the present case, the aridification of Iberia could not have provided enough fat-rich food for the SH hominins during the harsh winter (see e.g., Demuro et al., 2019) making them to resort to cave hibernation. Thus, the above argument is unfounded.

6.6. The recent humans that suffer from CKD-MBD do not hibernate

This is because they are provided food year round. As a result, they don't show any gaps (HZAGs) or layers of rickety osteoplaques (ROPs). Thus, the above argument is unfounded.

7. The physiological mechanism and the reconstruction of life history in the SH hominins

The rachitic metaphysis and the gaps (HZAGs) are evidence of hypocalcemia, osteoid formed in constant darkness due to cavernous conditions and hypercortisolism due to cold. The resultant increases in PTH may account for the pathologies described in fossil bears, living hibernators, and the SH hominins.

Thus, the simplified mechanism in poorly tolerated hibernation for cave-overwintering hominins during extreme glacial times as in SH would have been as follows: frigid conditions and food scarcity anticipated for the coming glacial winter, would have made these hominins to seek refuge in the Atapuerca caves and use them as hibernacula. Initially, high plasma cortisol due to constant darkness and cold would trigger lipolysis, which would have provided endogenous energy and vitamin D for calcium homeostasis. Thus, vitamin D would initially be substituted by that released from fat to suppress bone resorption and prevent bone loss. The metabolic homeostasis continues until all fat and its fat-soluble vitamin D are depleted thus, reaching a state of vitamin D insufficiency and deficiency that would have caused hypocalcemia, hyperphosphatemia, and osteoid formation. This would increase PTH secretion in such levels as to cause prolonged 2HPT, increased bone resorption, rickets, OF, CPPD, ROD and arrested growth, all associated with seasonal CKD-MBD (Ketteler et al., 2018; Moe et al., 2006). This is the state of poorly tolerated hibernation in which the body temperature cannot be sustained above a critical point and hibernation terminates or the individual is unable to arouse and dies or dies just after arousal from hibernation as it happens in some hibernators especially the young ones. During this state, the HZAGs and the ROPs are formed. The absence of fire and the raw meat diets of the SH hominins would have made things worse due to lack of Ca. Among SH hominins, the CKD-MBD was a recurrent disease, apparently on a seasonal basis because of glacial winters in the high seasonality area of Atapuerca and its high altitude. In this frigid environment, the cold and the constant darkness would have affected their physiology and therefore the ability of this human species to adapt to famine. It is therefore likely that they would have acquired genes and/or developed strategies, such as prehibernation fattening and hibernation suitable for countering the threat of famine periodically posed to their functional integrity and survival.

On arousal, the mechanism is reversed: those hominins that survived, get out of the cavernous hibernacula to replenish their stores of fat, vitamin D, and calcium thus suppressing PTH secretion. At the same time, the CKD-MBD pathologies are healing and growth takes place (in the adolescent ones). Fat starts to accumulate for the coming winter. However, should the fat reserves are not enough for a successful hibernation to occur e.g., in frigid climatic conditions and food scarcity, complete healing may not be achieved leading to a vicious cycle. In this case the individuals would enter hibernation with less fat than the previous year, a situation that might have been lethal for some of them. This is only the core of this pathophysiological mechanism as many aspects are unknown since more skeletal material and studies are required to better understand the physiopathogenesis of hibernation and cryomedicine in this extinct human species.

8. Conclusions

Because:

- the SH hominins lived in high-altitude caves during the most severe glaciation in the last 1 million years and their genetics is consistent with this;
- the SH bears were hibernatiing in order to survive in that frigid environment, the SH hominins would have to do the same since they were found in the same fossil horizon (LU-6) and context with that of the SH bears;
- hibernating cave conditions, such as constant darkness, winter famine and cold can trigger a series of metabolic pathways including cortisol secretion, lipolysis, hypocalcemia, vitamin D deficiency, decreases of growth hormone, 2HPT, resorption (OF) and ROD, evidenced by the formation of the annual gaps (i.e., the non-calcified osteoid termed here as Hibernational Zones of Arrested Growth, HZAGs);
- the lesions and the diseases in the SH hominins are the same or analogous to those of animal hibernators;
- the regularity, the extreme contrast and the distinctness of rachitic osteoplaques (ROPs) and mainly the HZAGs, in the cranial and long bones (Figs. 4–6) due to constant darkness, cold, high cortisol and annual growth arrest are diagnostic evidences of hibernation (Chinsamy et al., 1998; Klevezal, 1996);
- the gaps (HZAGs) between the lines of arrested growth (ROPs) occur only in animal hibernators such as bats (Kwiecinski et al., 1987 their Fig. 4b);
- the 4 sublayers of the superficial rachitic osteoplaque of Cranium 9 indicate 4 interbout arousals;
- Vitamin D deficiency and rickets alone do not produce annual HZAGs and ROPs;
- CPPD is evidence of lipolysis of BAT during interbout arousals;
- the healing deduced from brown tumours (BTs), subperiosteal new bone (PNB), and extensive enlargement of the Haversian canals is evidence of a post hibernation period and;
- the adolescent mortality distribution in SH is the result of famine during hibernation and is unique to hibernation

we deduce that the SH hominins were hibernating sometimes successfully (e.g., as in the adults) and sometimes unsuccessfully (as in some of the adolescents).

We have provided strong evidences for puberty and poorly tolerated hibernation in some of the adolescent SH hominins and successful hibernation in the adults. Since the mature individuals do not show any evidence of these lesions (with the exception of healing evidence such as brown tumours, subperiosteal new bone and enlargement of the Haversian canals), it follows that they had sufficient fat reserves to withstand the ill effects of hibernation. This is because they did not have to face the extra energy demands posed by adolescence. The healing that took place after their adolescence has made these lesions largely to disappear. As a result, the adult individuals were undergoing a more or less healthy and normal hibernation. Given the lesions' morphology, the histology, the pathognomonic features, the differential diagnosis, the extreme glacial environment they lived and the physiological effects of constant darkness and cold, we conclude that some of the SH fossil

hominins, especially those in adolescence, are the earliest known sufferers of a disease indistinguishable from the severe, acquired, and annual (seasonal) CKD-BMD that may have been caused only by poorly tolerated hibernation in dark cave hibernacula and recurrent (seasonal) periods of famine due to harsh climate. While many questions about their life histories and metabolism are still open, there is no doubt as to the immense consequences that hibernation has for hominin/human physiology and life history. Thus, under certain circumstances, some hominins may find themselves in metabolic states that help them to survive for long periods of time in frigid conditions with limited supplies of food and enough stores of body fat. The CKD-BMD with the different intensities of renal rickets, the gaps between the rachitic osteoplaques (i.e., the Hibernational Zones of Arrested Growth, HZAGs) and their sublayers, the "rotten fence post" sign, and the evidence of healing might be exploited as a new methodological tool for determining the presence of a pubertal growth spurt and seasonal hibernation in an extinct human species.

Acknowledgments

Our thanks are due to the late Don Ortner, who confirmed our diagnosis of rickets in Cranium 9. Drs Ana Gracia-Téllez and Jose Miguel Carretero for their assistance. The Department of History & Ethnology of the Democritus University of Thrace for granting one of us (A.B.) a sabbatical for the spring semester of 2006 in order to undertake this study. This study was financed by Ministerio de Economía y Competitividad, Spain Project PGC2018-093925-B-C33 (MCIU/AEI/FEDER, UE). The field work at the Atapuerca sites is financed by the Junta de Castilla y León. The funding source had no involvement in study design; in the collection, analysis and interpretation of data; in the writing of the report; and in the decision to submit the article for publication.

References

Adams, J.E., 1997. Radiology of Rickets and Osteomalacia. In: Feldman, D., Glorieux, F.H., Pike, J.W. (Eds.), Vitamin D. Academic Press, San Diego, pp. 619–642.
Adler, C.P., 2000. Bone Diseases. Springer, Berlin.
Aiello, L., 2006. Neanderthals, energetics and evolution. Symposium 150 years of Neanderthal discoveries. Terra Nostra 2, 63–66.
Aigner, J.S., 1985. Early Arctic settlements in North America. Sci. Am. 253 (5), 138–147 (156).
Alvarez-Lario, B., Macarrón-Vicente, J., 2001. Evolution of Uric Acid Metabolism in Humans. eLS.
Arsuaga, J.L., Martinez, I., Gracia, A., Lorenzo, C., 1997. The Sima de los Huesos crania (Sierra de Atapuerca, Spain). A comparative study. J. Hum. Evol. 33, 219–281.
Arsuaga, J.L., Martínez, I., Arnold, L.J., Aranburu, A., Gracia-Téllez, A., Sharp, W.D., et al., 2014. Neanderthal roots: cranial and chronological evidence from Sima de los Huesos. Science 344, 1358–1359.
Arsuaga, J.-L., Carretero, J.-M., Lorenzo, C., Gomez-Olivencia, A., Pablos, A., Rodriguez, L., et al., 2015. Postcranial morphology of the middle Pleistocene humans from Sima de los Huesos, Spain. PNAS 112 (37), 11524–11529.
Aufderheide, A.C., Rodriguez-Martin, C., 1998. Human Paleopathology. CambridgeUniversity Press.
Aviv, R.I., Rodger, E., Hall, C.M., 2002. Craniosynostosis. Clin. Radiol. 57 (2), 93–102.
Bailleul-Forestier, I., Davideau, J.L., Bourillor-Noble, I., Nessmann, C., Malaval, L., Berdal, A., 1994. Human dental development and vitamin D. In: Norman, A.W., Bouillon, R., Thomasset, M. (Eds.), Vitamin D. Walter de Gruyter, Berlin, pp. 871–872.
Bartsiokas, A., Arsuaga, J.L., 2018. Hibernation, puberty and chronic kidney disease in troglodytes from Spain half a million years ago. PeerJPreprints 6, e27370vl, http://dx.doi.org/10.7287/peerj.preprints.27370vl.
Bartsiokas, A., 2000. The eye injury of King Philip II and the skeletal evidence from the Royal Tomb II at Vergina. Science 288, 511–514.
Bereket, A., Casur, Y., Firat, P., Yordam, N., 2000. Brown tumor as a complication of secondary hyperparathyroidism in severe long-lasting vitamin D deficiency rickets. Eur. J. Pediatr. 159, 70–73.
Bermudez de Castro, J.M., Martinon-Torres, M., Carbonell, E., Sarmiento, S., Rosas, A., Van der Made, J., et al., 2004. The Atapuerca sites and their contribution to the knowledge of human evolution in Europe. Evol. Anthrop. 13, 25–41.
Bermudez de Castro, J.M., Rozzi, F.R., Martinon-Torres, M., Perez, S.S., Rosas, A., 2003. Patterns of dental development in Lower and Middle Pleistocene Hominins from Atapuerca (Spain). In: Thompson, J.L., Krovitz, G.E., Nelson, A.J. (Eds.), Patterns of Growth and development in the genus Homo. Cambridge University, pp. 246–270.
Bermúdez de Castro, J.M., Martin-Frances, I., Martinon-Torres, M., Arsuaga, J.L., 2020. The Sima de los Huesos Middle Pleistocene hominin site (Burgos, Spain). Estimation of the number of individuals. Anat. Rec. 1–15, http://dx.doi.org/10.1002/ar.24551.
Bermudez-de-Castro, J.-S., Martinon-Torres, M., Martin-Frances, L., Modesto-Mata, M., Martínez-de-Pinillos, M., García, C., et al., 2017. Homo antecessor: the state of the art eighteen years later. Quat. Int. 433, 22–31.
Berry, H.M., 1973. The lore and the lure o' the lamina dura. Radiology 109, 525–528.
Blackstone, E., Morrison, M., Roth, M.B., 2005. H2S induces a suspended animation-like state in mice. Science 308, 518.
Blanco, M.B., Dausmann, K.H., Faherty, S.L., Yoder, A.D., 2018. Tropical heterothermy is "cool": the expression of daily torpor and hibernation in primates. Evol. Anthropol. 27, 147–161.

Boia, M., Iacob, D., Manea, A., Dima, M., Cioboata, D., 2007. Etiologic and positive diagnosis of craniosynostosis. ISSN. 1221–7212.
Breuer, R., 1931. Zur Anatomie, Pathologie und Histologie der Zahne und der Kiefer von Ursus spelaeus. In: Abel, O., Kyrle, G. (Eds.), Die Drachenhoehle bei Mixnitz. Spelaeolog. Monogr., 7,8. Wien, (611-623), pp. 581–610.
Breukelen, F.V., Martin, S.L., 2002. Molecular adaptations in mammalian hibernators: unique adaptations or generalized responses? J. Appl. Physiol. 92, 2640–2647.
Brickley, M., Ives, R., 2008. The bioarchaeology of metabolic bone disease. Elsevier, Amsterdam.
Brown, D.C., Mulhausen, R.O., Andrew, D.J., Seal, U.S., 1971. Renal function in anesthetized dormant and active bears. Am. J. Physiol. 220 (1), 293–298.
Bybee, P.J., Lee, A.H., Lamm, E.-T., 2006. Sizing the Jurassic Theropod Dinosaur Allosaurus: assessing growth strategy and evolution of ontogenetic scaling of limbs. J. Morphol. 267, 347–359.
Caffey, J., 1978. Pedriatic X-Ray Diagnosis. Year Book Medical Publishers, Inc, Chicago.
Carey, H.V., Andrews, M.T., Martin, S.L., 2003. Mammalian hibernation: cellular and molecular responses to depressed metabolism and low temperature. Physiol. Rev. 83, 1153–1181.
Castanet, J., Baez, M., 1991. Adaptation and evolution in Gallotia lizards from the Canary islands: age, growth, maturity and longevity. Amphibia-Reptilia 12, 81–102.
Chan, J.C.M., Kodroff, M.B., Landwehr, D.M., 1981. Effects of 1,25-dihydroxyvitamin-D3 on renal function, mineral balance, and growth in children with severe chronic renal failure. Pediatrics 68 (4), 559–571.
Chinsamy, A., Rich, T., Vickers-Rich, P., 1998. Polar dinosaur histology. J. Vert. Paleont. 18 (2), 385–390.
Christian, J.J., Lloyd, J.A., Davies, D.E., 1965. The role of endocrines in the self-regulation of mammalian populations. Recent Prog. Hormone Res. 21, 501–578.
Cizza, G., Sejal, M., Terry, P., 2004. Serum markers of bone metabolism show bone loss in hibernating bears. Clin. Orthop. Rel. Res. 422, 281–283.
Cohen, M.M., 1988. Craniosynostosis update 1987. Am. J. Med. Genet. Suppl. 49–148.
Cool, S.M., Bennett, M.B., Romaniuk, K., 1994. Age estimation of pteropodid bats (Megachiroptera) from hard tissue parameters. Aust. Wildlife Res. 21 (3), 353–363.
Crutchlow, W.P., David, D.S., Whitsell, J., 1971. Multiple skeletal complications in a case of chronic renal failure treated by kidney homotransplantation. Am. J. Med. 50 (3), 390–394.
Debeljak, I., 2007. Fossil population structure and mortality of the cave bear from the Mokrica cave (North Slovenia). Acta Carsol. 36 (3), 475–484.
Dembert, M.L., 1982. Medical problems from cold exposure. Am. Fam. Physician 25 (1), 99–106.
Demuro, M., Arnold, L.J., Aranburu, A., Sala, N., Arsuaga, J.L., 2019. New bracketing luminescence ages constrain the Sima de los Huesos hominin fossils (Atapuerca, Spain) to MIS 12. J. Hum. Evol. 131, 76–95.
Dirks, R., 1980. Social responses during severe food shortages and famine. Curr. Anthropol. 21 (1), 21–44.
Dodds, W.J., Steinbach, H.L., 1968. Primary hyperparathyroidism and articular cartilage calcification. Am. J. Roentgenol. 104 (4), 884–892.
Donahue, S.W., Galley, S.A., Vaughan, M.R., Patterson-Buckendahl, P., Demers, L.M., Vance, J.L., et al., 2006. Parathyroid hormone may maintain bone formation in hibernating black bears (Ursus americanus) to prevent disuse osteoporosis. J Exp Biol 209, 1630–1638.
Donahue, S.W., Vaughan, M.R., Demers, L.M., Donahue, H.J., 2003. Serum markers of bone metabolism show bone loss in hibernating bears. Clin. Orthop. Rel. Res. 408, 295–301.
Doty, S.B., Nunez, E.A., 1985. Activation of osteoclasts and the repopulation of bone surfaces following hibernation in the bat. Myotis lucifugus. The Anatomical Record 213, 481–495.
Dreizen, S., Levy, B.M., Bernick, S., Hampton, J.K., Kraintz, L., 1967. Periodontal bone changes in marmosets with osteomalacia and hyperparathyroidism. Israel J. Med. Sci. 3 (5), 731–738.
Ducy, P., Schinke, T., Karsenty, G., 2000. The osteoblast: a sophisticated fibroblast under central surveillance. Science 289, 1501–1504.
Duggan, C., Keener, E., Gay, B., 1970. Secondary Craniosynostosis. Am. J. Roentegenol. 19, 277–293.
Duteroo, H.S., 1991. An Atlas of Dentition in Childhood. Wolfe Publishing Ltd.
Fletcher, P.D., Scopp, I.W., Hersh, R.A., 1977. Oral manifestations of secondary hyperparathyroidism related to long-term hemodialysis therapy. Oral Surg. Oral Med. Oral Pathol. 43 (2), 218–226.
Follis, R.H., 1950. Renal rickets and osteitis fibrosa in children and adolescents. Bull. Johns Hopkins Hosp. 87 (6), 593–615.
Freyschmidt, J., Wiens, J., Brossmann, J., Sternberg, A., 2003. Freyschmidt's 'Koehler/Zimmer' Borderlands of normal and early pathological findings in skeletal radiography, 5th ed. Thieme, Stuttgart.
Fumagalli, M., Moltke, I., Grarup, N., Racimo, F., Bjerregaard, P., Jørgensen, M.E., et al., 2015. Greenlandic Inuit show genetic signatures of diet and climate adaptation. Science 349 (6254), 1343–1347.
Garcia, N., Arsuaga, J.L., 2010. The Sima de los Huesos (Burgos, Northern Spain): Paleoenvironment and habitats of Homo heidelbergensis during the Middle Pleistocene. Quaternary Science Reviews 30, 1413–1419.
Geiser, F., 1995. Hibernation versus daily torpor in mammals and birds: Physiological variables and classification of torpor patterns. Physiol. Zoo 68, 935–966.
Goldman, A.B., Lane, J.M., Salvati, E., 1978. Slipped capital femoral epiphyses complicating renal osteodystrophy: a report of three cases. Radiology 126, 333–339.
Gomez Olivencia, A., 2009. Estudios paleobiologicos sobre la columna vertebral y la caja toracica de los humanos fosiles del Pleistoceno, con especial referencia a los fosiles de la Sierra de Atapuerca. Tesis Doctoral. Universidad de Burgos.
Gomez Olivencia, A., Carretero, J.M., Arsuaga, J.L., Rodriguez-Garcia, L., Garcia-Gonzalez, R., Martinez, I., 2007. Metric and morphological study of the upper cervical spine from the Sima de los Huesos site (Sierra de Atapuerca, Burgow, Spain. J. Hum. Evol. 53 (1), 6–25.
Gracia, A., Arsuaga, J.L., Martínez, I., Lorenzo, C., Carretero, J.M., Bermúdez de Castro, J.M., et al., 2009. Craniosynostosis in the Middle Pleistocene human Cranium 14 from the Sima de los Huesos, Atapuerca, Spain. Proc. Natl. Acad. Sci. 106 (16), 6573–6578, http://dx.doi.org/10.1073/pnas.0900965106.

Gracia, A., Martinez-Lage, J.F., Arsuaga, J.L., Martinez, I., Lorenzo, C., Pérez-Espejo, M.-Á., 2010. The earliest evidence of true lambdoid craniosynostosis: the case of "Benjamina", a Homo heidelbergensis child. Childs Nerv. Syst., http://dx.doi.org/10.1007/s00381-010-1133-y.
Grech, P., Martin, T.J., Barrington, N.A., Ell, P.J., 1985. Diagnosis of Metabolic bone disease. Chapman and Hall Medical, London.
Gustafson, A.W., Belt, W.D., 1981. The adrenal cortex during activity and hibernation in the male little brown bat, Myotis lucifugus ludifugus: annual rhythm of plasma cortisol levels. Gen. Comp. Endocrinol. 44, 269–278.
Haller, A.C., Zimny, M.L., 1977. Effects of hibernation on interradicular alveolar bone. J. Dental Res. 56 (12), 1552–1557.
Hamilton, S., Knickerbocker, W.J., 1982. Periarticular erosions in the hands and wrists in haemodialysis patients. Clin. Radiol. 323, 19–24.
Hashimoto, M., 2006. Is hibernation a possible phenomenon in humans? Nippon Seirigaku Zasshi 68 (11), 395–396.
Heath, D.A., Martin, D.J., 1970. Periosteal new bone formation in hyperparathyroidism associated with renal failure. Br. J. Radiol. 43, 517–521.
Hittel, D.S., Storey, K.B., 2002. Differential expression of mitochondria-encoded genes in a hibernating mammal. J. Exp. Biol. 205, 1625–1631.
Hock, R.J., 1960. Seasonal variations in physiologic functions of arctic ground squirrels and black bears. Bull. Mus. Comp. Zool. 124, 155–171.
Hoehn, K., Marieb, E.N., 2010. Human Anatomy & Physiology. Benjamin Cummings, San Francisco.
Hong, S.K., 1956. Renal function during hypothermia and hibernation. Am. J. Physiol. 188 (1), 137–150.
Hsu, A.C., Kooh, S.W., Fraser, D., Cumming, W.A., Fornasier, V.L., 1982. Renal osteodystrophy in children with chronic renal failure: an unexpectedly common and incapacitating complication. Pediatrics 70 (5), 742–750.
Huerta-Sánchez, E., Jin, X., Asan, Bianba, Z., Peter, B.M., Vinckenbosch, N., et al., 2014. Altitude adaptation in Tibetans caused by introgression of Denisovan-like DNA. Nature 512 (7513), 194–197.
Jaffe, H.L., 1972. Metabolic, Degenerative, and Inflammatory Diseases of Bones and Joints. Lea & Febiger, Philadelphia.
Jaffe, H.L., Bodansky, A., Blair, J.E., 1931. Fibrous osteodystrophy (osteitis fibrosa) in experimental hyperparathyroidism of Guinea-pigs. Arch. Pathol. 11, 207–228.
Jaffe, H.L., Bodansky, A., Blair, J.E., 1932. The influence of age and of duration of treatment on the production and repair of bone lesions in experimental hyperparathyroidism. J. Exp. Med. 55, 139–154.
Johnson, C., Graham, C.B., Kingsbury Curtis, F., 1967. Roentgenographic manifestations of chronic renal disease treated by periodic hemodialysis. A.J.R. 101 (4), 915–926.
Johnson, R.J., Andrews, P., 2015. The fat gene. Sci. Am. 313 (4), 64–69.
Katz, A.I., Hampers, C.L., Merrill, J.P., 1969. Secondary hyperparathyroidism and renal osteodystrophy in chronic renal failure. Medicine 48 (5), 333–374.
Kaye, M., Prichard, J.E., Halpenny, G.W., Light, W., 1960. Bone disease in chronic renal failure with particular reference to osteosclerosis. Medicine 39, 157–190.
Ketteler, M., Block, G.A., Evenepoel, P., Fukagawa, M., Herzog, C.A., McCann, L., et al., 2018. Diagnosis, Evaluation, Prevention, and Treatment of Chronic Kidney Disease–Mineral and Bone Disorder: Synopsis of the Kidney Disease: Improving Global Outcomes 2017 Clinical Practice Guideline Update. Ann. Internal Med. 168 (6), 422–430.
Kirkwood, J.R., Ozonoff, M.B., Steinbach, H.L., 1972. Epiphyseal displacement after metaphyseal fracture in renal osteodystrophy. Am. J. Roentgenol. 115 (3), 547–554.
Kitaba, I., Harada, M., Hyodo, M., Katoh, S., Sato, H., Matsushita, M., 2011. MIS 21 and the Mid-Pleistocene climate transition: climate and sea-level variation from a sediment core in Osaka Bay, Japan. Palaeogeogr. Palaeoclimatol. Palaeoecol. 299, 227–239.
Klepinger, L.L., 1979. Paleopathologic evidence for the evolution of rheumatoid arthritis. AJPA 50, 119–122.
Klevezal, G.A., 1996. Recording structures of mammals. Bakelma A.A, Rotterdam.
Knaggs, R.L., 1923. Osteitis fibrosa. Br. J. Surg. 10, 487–500.
Kobbe, S., Ganzhorn, J.U., Dausmann, K.H., 2011. Extreme individual flexibility of heterothermy in free-ranging Malagasy mouse lemurs (Microcebus griseorufus). J. Comp. Physiol. B 181, 165–173.
Krajcarz, M.T., Krajcarz, M., Marciszak, A., 2014. Paleoecology of Bears from MIS 8–MIS 3 Deposits of Biśnik Cave Based on Stable Isotopes (δ13C, δ18O) and Dental Cementum Analyses. Quat. Int. 326, 114–124, http://dx.doi.org/10.1016/j.quaint.2013.10.067.
Krempien, B., Mehls, O., Ritz, E., 1974. Morphological studies on pathogenesis of epiphyseal slipping in uremic children. Virchows Archiv. A Path. Anat. Histol. 362, 129–143.
Krook, L., Barrett, R.B., 1962. Simian bone disease—A secondary hyperparathyroidism. Cornell Vet. 52, 459–492.
Krovitz, G.E., Thompson, J.L., Nelson, A.J., 2003. Hominid growth and development from australopithecines to Middle Pleistocene Homo. In: Thompson, J.L., Krovitz, G.E., Nelson, A.J. (Eds.), Patterns of Growth and development in the genus Homo. Cambridge University Press, pp. 271–292.
Krystufek, B., Pistotnik, M., Casar, K.S., 2005. Age determination and age structure in the edible dormouse Glis glis based on incremental bone lines. Mammal Rev. 35 (2), 210–214.
Kurten, B., 1969. Cave bears. Stud. Speleol. 2 (1), 13–24.
Kwiecinski, G.G., Krook, L., Wimsatt, W.A., 1987. Annual skeletal changes in the little brown bat, Myotis lucifugus lucifugus, with particular reference to pregnancy and lactation. Am. J. Anat. 178, 410–420.
Kwon, D.S., Spevak, M.R., Fletcher, K., Kleinman, P.K., 2002. Physiologic subperiosteal new bone formation: prevalence, distribution, and thickness in neonates and infants. AJR 179, 985–988.
Lee, C.C., 2007. Constant darkness is a mammalian biological signal. Cold Spring Harbor Symp. Quant. Biol. 77, 287–291.
Lee, C.C., 2008. Is human hibernation possible? Annu Rev Med 59, 177–186.
Lee, V.S., Webb, M.S., Martinez, S., McKay, C.P., Leight, G.S., 1996. Uremic Leontiasis Ossea: "Bighead" disease in humans? Radiologic, clinical, and pathologic features. Radiology 199, 233–240.
Leigh, S.R., 1996. Evolution of growth spurts. AJPA 101, 455–474.
Leonard, W.R., Sorensen, M.V., Galloway, V.A., Spencer, G.J., Mosher, M.J., Osipova, L., et al., 2002. Climatic influences on basal metabolic rates among circumpolar populations. Am. J. Hum. Biol. 14 (5), 609–620.

Lewis, M.E., 2007. The Bioarchaeology of Children. Cambridge University Press.
Li, Y.C., Pirro, A.E., Amling, M., Delling, G., Baron, R., Bronson, R., et al., 1997. Targeted ablation of the vitamin D receptor: an animal model of vitamin D-dependent rickets type II with alopecia. Proc. Natl. Acad. Sci. USA 94, 9831–9835.
Marini, M., Vidiri, A., Guerrisi, R., Campodonico, F., Ponzio, R., 1992. Progress of brown tumors in patients with chronic renal insufficiency undergoing dialysis. Eur. J. Radiol. 14, 67–71.
Markel, S.F., Hart, W.R., 1982. Arthropathy in calcium pyrophosphate dihydrate crystal deposition disease. Arch. Pathol. Lab. Med. 106, 529–533.
Mawer, E.B., Backhouse, J., Holman, C.A., Lumb, G.A., Stanbury, S.W., 1972. The distribution and storage of vitamin D and its metabolites in human tissues. Clin. Sci. 43, 413–431.
Maxwell, D.R., Spolnik, K.J., Cockerill, E.M., Patterson, S.S., Kleit, S.A., 1977. Roentgenographic manifestations of maxillomandibular renal osteodystrophy. Nephron 41, 223–229.
Mays, S., Brickley, M., Ives, R., 2007. Skeletal evidence for hyperparathyroidism in a 19th century child with rickets. Int. J. Osteoarchaeol. 17, 73–81.
McGee-Lawrence, M.E., Carey, H.V., Donahue, S.W., 2008. Mammalian hibernation as a model of disuse osteoporosis: the effects of physical inactivity on bone metabolism, structure, and strength. Am. J. Physiol. Regul. Integr. Comp. Physiol. 295, R1999–R2014.
Meema, H.E., Oreopoulos, D.G., Murray, T.M., 1986. Periosteal resorption and periosteal neostosis: Comparison of normal subjects and renal failure patients on chronic ambulatory peritoneal dialysis using MOP-3 image analysis system and a grading method. Skelet. Radiol. 15, 14–20.
Meema, H.E., Oreopoulos, D.G., Rabinovich, S., Husdan, H., Rapoport, A., 1974. Periosteal new bone formation (periosteal neostosis) in renal osteodystrophy. Radiology 110, 513–522.
Meema, H.E., Oreopoulos, D.G., 1983. The mode of progression of subperiosteal resorption in the hyperparathyroidism of chronic renal failure. Skelet. Radiol. 10, 157–160.
Mehls, O., Ritz, E., Krempien, B., Gilli, G., Link, K., Willich, E., et al., 1975. Slipped epiphyses in renal osteodystrophy. Arch. Dis. Childhood 50, 545–554.
Meredith, H.C., Hungerford, G.D., Rittenberg, G.M., 1978. The skull in renal osteodystrophy. Skelet. Radiol. 3, 105–107.
Meyer, M., Fu, Q., Aximu-Petri, A., Glocke, I., Nickel, B., Arsuaga, J.-L., et al., 2014. A mitochondrial genome sequence of a hominin from Sima de los Huesos. Nature 505, 403–406.
Moe, S., Drüeke, T., Cunningham, J., Goodman, W., Martin, K., Olgaard, K., et al., 2006. Definition, evaluation, and classification of renal osteodystrophy: a position statement from Kidney Disease: Improving Global Outcomes (KDIGO). Kidney Int. 69 (11), 1945–1953.
Moore, K., Ross, A., 2017. Frontal sinus development and juvenile age estimation. Anat. Rec. 300 (9), 1609–1617.
Morris, P., 1972. A review of mammalian age determination methods. Mammal Rev. 2 (3), 69–104.
Murphey, M.D., Sartoris, D.J., Quale, J.L., Pathria, M.N., Martin, N.L., 1993. Musculoskeletal manifestations of chronic renal insufficiency. RadioGraphics 13, 357–379.
Naidich, J.B., Karmel, M.I., Mossey, R.T., Bluestone, P.A., Stein, H.L., 1987. Osteoarthropathy of the hand and wrist in patients undergoing long-term hemodialysis. Radiology 164, 205–209.
Nedergaard, J., Cannon, B., 1990. Mammalian hibernation. Phil. Trans. R. Soc. Lond. B. 326, 669–686.
Nelson, R.A., Folk, G.E., Pfeiffer, E.W., Craighead, J.J., Jonkel, C.J., Steiger, D.L., 1983. Behavior Biochemistry, and Hibernation in Black, Grizzly, and Polar Bears. Int. Conf. Bear Res. Manage. 5, 284–290.
Netter, F.H., 1987. The CIBA collection of medical illustrations. Vol. 8. Musculoskeletal system. Part I: Anatomy, Physiology and Metabolic disorders. CIBA-GEIGY Corporation: Summit.
Nilsson, L.M., Winkvist, A., Brustad, M., Jansson, J.H., Johansson, I., Lenner, P., et al., 2012. A traditional Sami diet score as a determinant of mortality in a general northern Swedish population. Int. J. Circumpolar Health 71 (0), 1–12, http://dx.doi.org/10.3402/ijch.v71i0.18537 (PMID: 22584519; PMCID: PMC3417469).
Nunez, E.A., Gerzhon, M.D., 1972. Synthesis and storage of serotonin by parafollicular (C) cell of the thyroid gland of active, prehibernating and hibernating bats. Endocrinology 90, 154–170.
Nunez, E.A., Whalen, J.P., Krook, L., 1971. An ultrastructural study of the natural secretory cycle of the parathyroid gland of the bat. Am. J. Anat. 134, 459–480.
Olmastroni, M., Seracini, D., Lavoratti, G., Marin, E., Masi, A., Vichi, G., 1997. Magnetic resonance imaging of renal osteodystrophy in children. Pediatr. Radiol. 27, 865–868.
Ortner, D.J., Utermohle, C.J., 1981. Polyarticular inflammatory arthiritis in a pre-Columbian skeleton from Kodiak Island, Alaska, U.S.A. AJPA 56, 23–31.
Ortner, D.J., Mays, S., 1998. Dry-bone manifestations of rickets in infancy and early childhood. Intl. J. Osteoarchaeol. 8, 45–55.
Pääkkönen, T., Leppäluoto, J., 2002. Cold exposure and hormonal secretion: a review. Int. J. Circumpolar Health 61 (3), 265–276.
Padian, K., de Ricqles, A.J., Horner, J.R., 2001. Dinosaurian growth rates and bird origins. Nature 412, 405–408.
Parfitt, A.M., 1972. Renal Osteodystrophy. Orthop. Clin. N. Am. 3 (3), 681–698.
Peabody, F.E., 1961. Annual growth zones in living and fossil vertebrates. J. Morph. 108, 11–62.
Pengelley, E.T., Fisher, K.C., 1961. Rhythmical arousal from hibernation in the golden-mantled ground squirrel. Citellus lateralis tescorum. Can. J. Zoo 39 (1), 105–120.
Perret, M., Predine, J., 1984. Effects of long-term grouping on serum cortisol levels in Microcebus murinus(Prosimii). Horm. Behav. 18, 346–358.
Pettifor, J.M., Daniels, E.D., 1997. Vitamin D deficiency and nutritional rickets in children. Chapter 42. In: Feldman, D., Glorieux, F.H., Pike, J.W. (Eds.), Vitamin D. Academic Press, San Diego, pp. 663–678.
Pezeshk, P., Carrino, J.A., 2009. Chapter 3, Rickets and Osteomalacia. In: Weisman, B.N.M. (Ed.), Imaging of arthritis and metabolic bone disease. Saunders Elsevier.
Pitt, M.J., 1988. Rickets and Osteomalacia. In: Resnick, D., Niwayama, G. (Eds.), Diagnosis of bone, joint disorders, 2nd ed., 8, W.B., Saundres, Philadelphia, pp. 2086–2126.
Potter, D.E., Wilson, C.J., Ozonoff, M.B., 1974. Hyperparathyroid bone disease in children undergoing long-term hemodialysis; treatment with vitamin D. J. Pediatrics 85 (1), 60–66.

Power, R.C., 2019. Neanderthals and Their Diet. In: eLS. John Wiley & Sons, Ltd, Chichester1–9, http://dx.doi.org/10.1002/9780470015902.a0028497.
Racimo, F., Gokhman, D., Fumagalli, M., Ko, A., Hansen, T., Moltke, I., et al., 2017. Archaic adaptive introgression in TBX15/WARS2. Mol. Biol. Evol. 34 (3), 509–524.
Raisz, L.G., 1984. Studies on bone formation and resorption in vitro. Hormone Res. 20, 22–27.
Ray, S., Chinsamy, A., Bandyopadhyay, S., 2005. Lystrosaurus murrayi (Therapsida, Dicynodontia): bone histology, growth and lifestyle adaptations. Paleontology 48 (6), 1169–1185.
Reilly, B.J., Leeming, J.M., Fraser, D., 1964. Craniosynostosis in the rachitic spectrum. J. Pediatrics 64 (3), 396–405.
Renton, P., 1998. Radiology of rickets, osteomalacia and hyperparathyroidism. Hospital Med. 59 (5), 399–403.
Resnick, D., Niwayama, G., 1995a. Calcium Pyrophosphate dihydtrate (CPPD) crystal deposition disease. In: Resnick, D. (Ed.), Diagnosis of bone and joint disorders. 3rd ed. W.B. Saunders Company, Philadelphia, pp. 1556–1614.
Resnick, D., Niwayama, G., 1995b. In: Resnick, D. (Ed.), Parathyroid disorders and renal osteodystrophy. Diagnosis of bone and joint disorders. W.B. Saunders Company, Philadelphia, pp. 2012–2074.
Resnick, D., 1978. Abnormalities of bone and soft tissue following renal transplantation. Semin. Roentgenol. 13 (4), 329–340.
Resnick, D., 1995. Diagnosis of bone and joint disorders, 3rd ed. W.B. Saunders Company, Philadelphia.
Resnick, D., Niwayama, G., 1976. Subchondral resorption of bone in renal osteodystrophy. Radiology 118, 315–321.
Ricqles, A., De, F.J., Meunier, J., Castanet, H., Francillon-Vieillot, 1991. Comparative microstructure of bone. Bone matrix and bone specific products. BK Hall (Ed). Bone 3, 1–178.
Ritz, E., Krempien, B., Mehls, O., Malluche, H., 1973. Skeletal abnormalities in chronic renal insufficiency before and during maintenance hemodialysis. Kidney Int. 4, 116–127.
Robinson, P.J.A., Walker, G.S., Peacock, M., McLachlan, M.S.F., Davison, A.M., 1982. 1-alpha-hydroxy vitamin D in dialysis bone disease: radiological changes after 6 and 12 months of treatment. Clin. Radiol. 33, 9–17.
Rosen, D.M., Luben, R.A., 1983. Multiple hormonal mechanisms for the control of collagen synthesis in an osteoblast-like cell line, MMB-1. Endocrinology 112 (3), 992–999.
Rosen, E.D., Spiegelman, B.M., 2006. Adipocytes as regulators of energy balance and glucose homeostasis. Nature 444, 847–853.
Rosenstreich, S.J., Rich, C., Volwiler, W., 1971. Deposition in and release of vitamin D3 from body fat: evidence for a storage site in the rat. J. Clin. Investig. 50, 679–687.
Rosenthall, L., Rush, C., 1986. Radiophosphate disclosure of subperiosteal bone formation in renal osteodystophy. J. Nucl. Med. 27, 1572–1576.
Rothschild, B.M., Martin, L.D., 1993. Paleopathology: disease in the fossil record. CRC Press, BocaRaton.
Ryan, L.M., Kurup, I.V., Derfus, B.A., Kushnaryov, V.M., 1992. ATP-Induced Chondrocalcinosis. Arthritis Rheum. 35 (12), 1520–1525.
Sala, N., Arsuaga, J.L., Pantoja-Perez, A., Pablos, A., Martinez, I., Quam, R.M., et al., 2015. Lethal interpersonal violence in the Middle Pleistocene. PLOS One 10 (5), e0126589.
Schiller, A.L., 1994. Bones and joints. In: Rubin, E., Farber, J.L. (Eds.), Pathology. 2nd ed. J.B., Lippincott, Philadelphia, pp. 1273–1346.
Schulke, O., Ostner, J., 2007. Physiological ecology of cheirogaleid primates: variation in hibernation and torpor. Acta Ethol. 10, 13–21.
Schultz, M., 2003. Light microscopic analysis in skeletal paleopathology. In: Ortner, D.J. (Ed.), Identification of pathological conditions in human skeletal remains. 2nd ed. Academic Press, Amsterdam, pp. 73–108.
Schultz, M., 2006. Results of the anatomical-palaeopathological investigations on the Neanderthal skeleton from Kleine Feldhofer Grotte (1856) including the new discoveries from 1997/2000. Schmitz R.W., Neanderthal277–318 (1856–2006).
Schwartz, E.E., Lantieri, R., Teplick, J.G., 1977. Erosion of the inferior aspect of the clavicle in secondary hyperparathyroidism. Am. J. Roentgenol. 129, 291–295.
Seger, R.L., Cross, R.A., Rosen, C.J., Causey, R.C., Gundberg, C.M., Carpenter, T.O., et al., 2011. Investigating the mechanism for maintaining eucalcemia despite immobility and anuria in the hibernating American black bear (Ursus americanus). Bone 49 (6), 1205–1212.
Shapiro, R., 1972. Radiologic aspects of renal osteodystrophy. Radiol. Clin. N. Am. X (3), 557–568.
Slatopolsky, E., Delmez, J.A., 1998. Renal osteodystrophy. In: Avioli, L., Krane, S. (Eds.), Metabolic bone disease and clinically related disorders. Academic press, San Diego, pp. 443–464.
Soderholm, G., Lyssell, L., Svensson, A., 1974. Changes in the jaws in chronic renal insufficiency and haemodialysis. Report of a case. J. Clin. Periodontol. 1, 36–42.
Soliman, A.T., Madina, E.H., Morsi, M.R., 1996. Radiological, biochemical, and hormonal changes in malnourished children with rachitic manifestations. J. Trop. Pedriatr. 42, 34–37.
Steinbach, H.L., Noetzli, M., 1964. Roentgen appearance of the skeleton in osteomalacia and rickets. Am. J. Roentgen. Nucl. Med. 91 (5), 955–972.
Steinbach, H.L., Kolb, F.O., Crane, J.T., 1959. Unusual Roentgen manifestations of osteomalacia. AJR 82 (5), 875–886.
Steinbach, H.L., Gordan, G.S., Eisenberg, E., Crane, J.T., Silverman, S., Goldman, L., 1961. Primary hyperparathyroidism: a correlation of Roentgen, clinical, and pathologic features. Am. J. Roentgen. 86 (2), 329–343.
Steinberg, B., Singh, I.J., Mitchel, O.G., 1981. The effects of cold-stress, hibernation, and prolonged inactivity on bone dynamics in the golden hamster, Mesocricetus auratus. J. Morphol. 167, 43–51.
Stenvinkel, P., Jani, A.H., Johnson, R.J., 2013. Hibernating bears (Ursidae): metabolic magicians of definite interest for the nephrologist. Kidney Int. 83 (2), 207–212.
Sundaram, M., 1989. Renal osteodystrophy. Skeletal Radiol. 18, 415–426.
Sundaram, M., Joyce, P.F., Shields, J.B., Riaz, M.A., Sagar, S., 1979. Terminal phalangeal tufts: earliest site of renal osteodystrophy findings in hemodialysis patients. AJR 133, 25–29.
Suzuki, H.K., 1963. Studies on the osseous system of the slider turtle. Ann. N.Y. Acad. Sci. 109, 351–410.
Swischuk, L.E., Hayden, C.K., 1979. Rickets: a Roentgenographic scheme for diagnosis. Pediatr. Radiol. 8, 203–208.
Tamarozzi, R., Bedani, P.L., Scutellari, P.N., Orzincolo, C., Pinna, L., Farinelli, A., 1984. Periosteal new bone in uraemic osteodystrophy. Skeletal Radiol. 11, 50–53.

Tardieu, C., 1998. Short adolescence in early hominids: infantile and adolescent growth of the human femur. AJPA 107, 163–178.
Teall, C.G., 1928. A radiological study of the bone changes in renal infantilism. Br. J. Radiol. 1, 49–58.
Teng, C.T., Nathan, M.H., 1960. Primary hyperparathyroidism. Am. J. Roentgenol. 83 (4), 716–731.
Tigges, S., Nance, E.P., Carpenter, W.A., Erb, R., 1995. Renal osteodystrophy: imaging findings that mimic those of other diseases. AJR 165, 143–148.
Tsushima, Y., Nishizawa, H., Tochino, Y., Nakatsuji, H., Sekimoto, R., Nagao, H., et al., 2013. Uric acid secretion from adipose tissue and its increase in obesity. J. Biol. Chem. 288 (38), 27138–27149.
Turvey, S.T., Green, O.R., Holdaway, R.N., 2005. Cortical growth marks reveal extended juvenile development in New Zealand moa. Nature 435, 940–943.
van Marken Lichtenbelt, W.D., Vanhommerig, J.W., Smulders, N.M., Drossaerts, J.M.A.F.L., Kemerink, G.J., Bouvy, N.D., et al., 2009. Cold-activated brown adipose tissue in healthy men. N. Engl. J. Med. 360, 1500–1508.
Vestergaard, P., Støen, O.-G., Swenson, J.E., Mosekilde, L., Heickendorff, L., Fröbert, O., 2011. Vitamin D status and bone and connective tissue turnover in brown bears (Ursus arctos) during hibernation and the active state. PLoS ONE 6 (6), 1–6.
Vigorita, V.J., 1999. Orthopaedic pathology. Lippincott Williams & Wilkins, Philadelphia.
Vigorita, V.J., Einhorn, T.A., Phelps, K.R., 1987. Microscopic bone pathology in two cases of surgically treated secondary hyperparathyroidism. Am. J. Surg. Path. 11, 205–209.
Vigorita, V.J., Anand, V.S., Einhorn, T.A., 1986. Sampling error in diagnosing hyperparathyroid changes in bone in small needle biopsies. Am. J. Surg. Pathol. 10 (2), 140–142.
Walsh, R.F., Karmiol, M., 1969. Oral roentgenographic findings in osteitis fibrosa generalisata associated with chronic renal disease. Oral Surg. Oral Med. Oral Pathol. 28 (2), 273–281.
Wang, P.I., Marcus, J.R., Fuchs, H.E., Mukundan Jr., S., 2007. Craniosynostosis Secondary to Rickets: Manifestations on Computed Tomography. Radiol. Case Rep. 2 (3), 43, http://dx.doi.org/10.2484/rcr.v2i3.43.
Wang, R., 2010. Error! Hyperlink reference not valid Sci. Am. 302 (3), 51–55.
Webster, A., Nagler, E.V., Morton, R.L., 2017. Chronic kidney disease. Lancet 389, 1238–1252.
Weller, M., Edeiken, J., Hodes, P.J., 1968. Renal osteodystrophy. Am. J. Roentgenol. 104, 354–363.
Wells, C., 1975. Prehistoric and historical changes in nutritional diseases and associated conditions. Prog. Food Nutr. Sci. 1 (11), 729–779.
Whalen, J.P., Krook, L., Nunez, E.A., 1972. A radiographic and histologic study of bone in the active and hibernating bat (Myotis lucifugus). Anatom. Rec. 172 (1), 97–107.
Wroe, S., Parr, W.C.H., Ledogar, J.A., Bourke, J., Evans, S.P., Fiorenza, L., et al., 2018. Computer simulations show that Neanderthal facial morphology represents adaptation to cold and high energy demands, but not heavy biting. Proc. R. Soc. B 285, 20180085, http://dx.doi.org/10.1098/rspb.2018.0085.
Wu, J., Bostrom, P., Sparks, L.M., Ye, L., Choi, J.H., Giang, A.-H., et al., 2012. Beige adipocytes are a distinct type of thermogenic fat cell in mouse and human. Cell 150, 366–376.
Zancanaro, C., Malatesta, M., Mannello, F., Vogel, P., Fakan, S., 1999. The kidney during hibernation and arousal from hibernation. A natural model of organ preservation during cold ischaemia and reperfusion. Nephrol. Dial. Transplant. 14, 1982–1990.
Zhang, J., Kaasik, K., Blackburn, M.R., Lee, C.C., 2006. Constant darkness is a circadian metabolic signal in mammals. Nature 439, 340–343.